

Arrow Project

Noa Rozendorn

Guided by

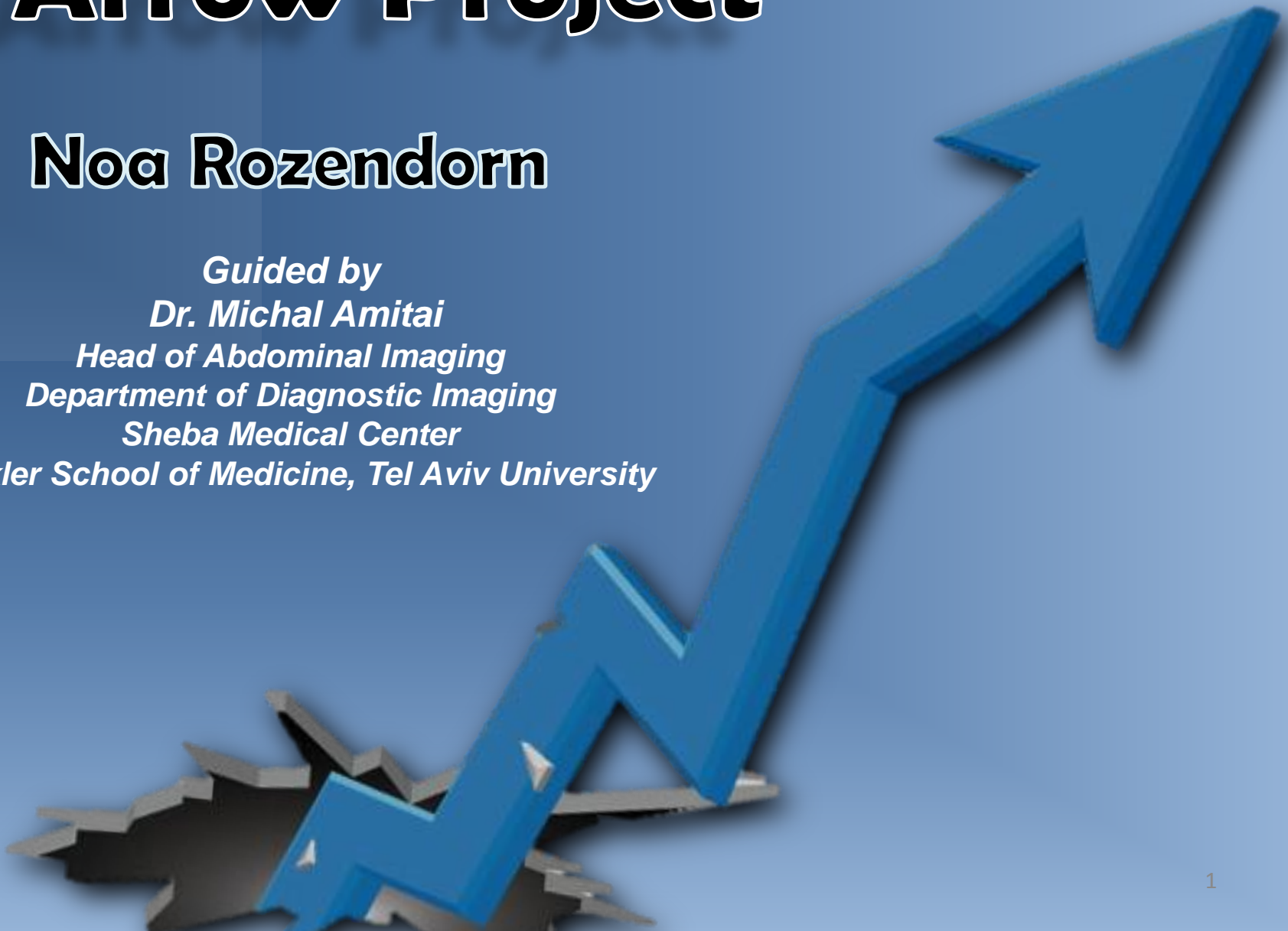Dr. Michal Amitai

Head of Abdominal Imaging

Department of Diagnostic Imaging

Sheba Medical Center

Sackler School of Medicine, Tel Aviv University



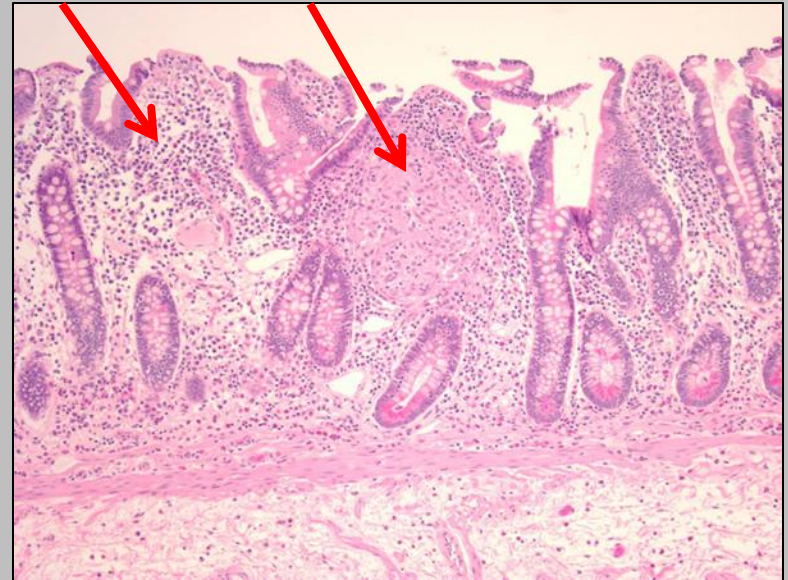
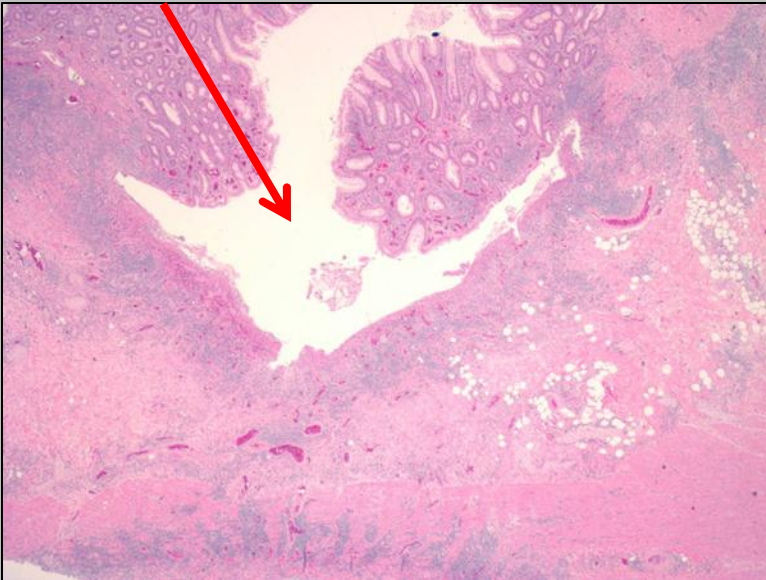My year...



- **SHARE study**
- Collaboration between gastroenterology and radiology departments
- 3 year prospective research study
- Developing an algorithm to predict relapse in Crohn's Disease (CD) patients

Crohn's Disease

- Chronic, Inflammatory disease of the small and or large bowel



- Multifactorial - Genetic and Environmental

Crohn's Disease

- Common age of diagnosis - 2nd decade of life
- Main symptoms: Diarrhea, Abdominal pain and Weight loss
- In Israel, an estimated number of 30,000 patients¹



Crohn's Disease

- Fluctuates between periods of exacerbation and remission
- Variable course
- Progression to a penetrating (abscess, fistula) or stricturing disease^{1, 2, 3}

1 – Behavior of Crohn's disease according to the Vienna classification: changing pattern over the course of the disease; Luis E. et al; *Gut* 2001

2 - Long-term evolution of disease behavior of Crohn's disease; Cosnes J et al.; *Inflamm Bowel Dis* 2002

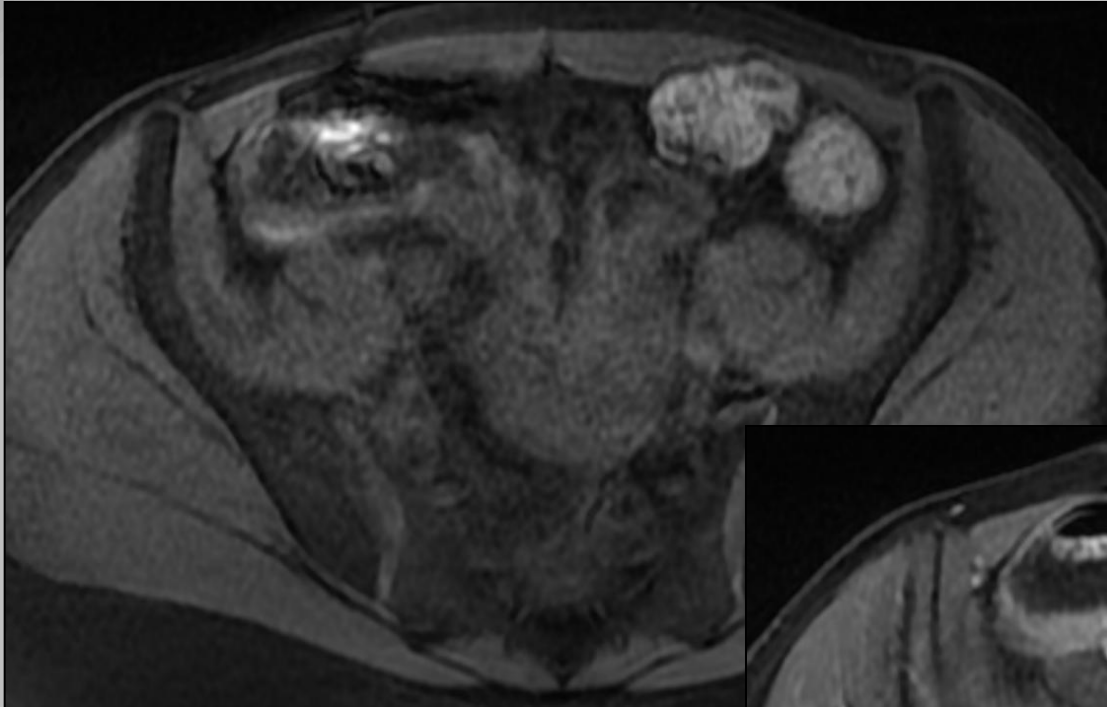
3-Perianal disease, small bowel disease, smoking, prior steroid or early azathioprine/biological therapy are predictors of disease behavior change in patients with Crohn's disease; Lakatos PL. et al.; *World J Gastroenterol* 2009

21y Old Female

- Diagnosed with CD at age 12 with symptoms of abdominal pain and weight loss
- Treated over the years with Imuran (Immunosuppressive drug)
- Enrolled to the SHARE study in remission

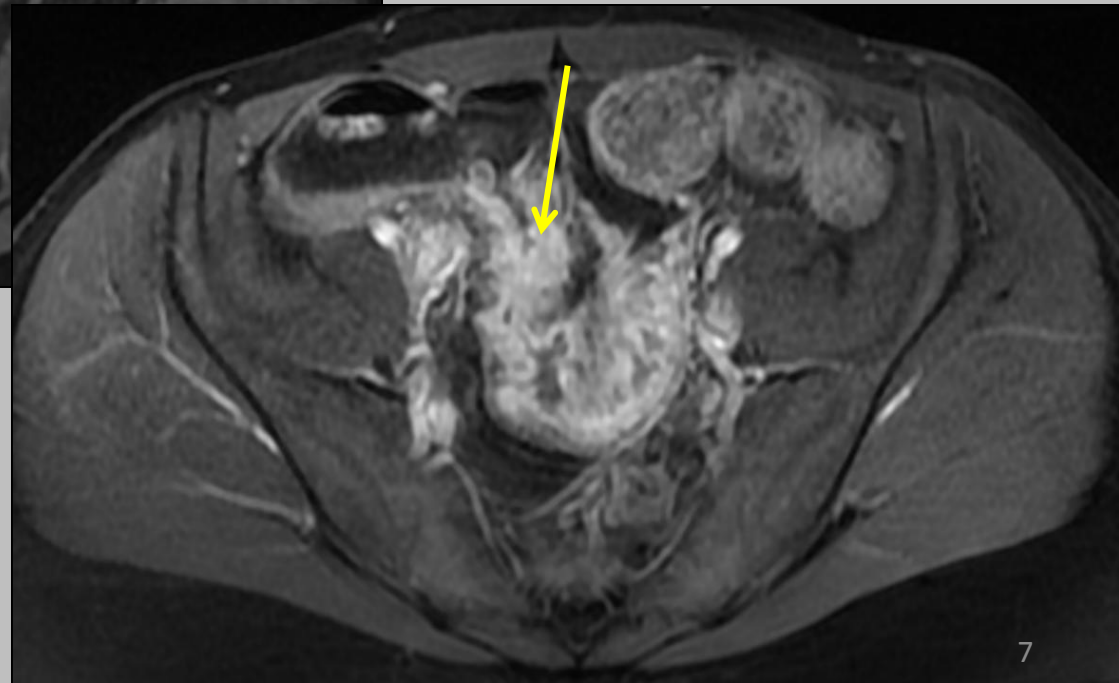
21y Old Female – MRE

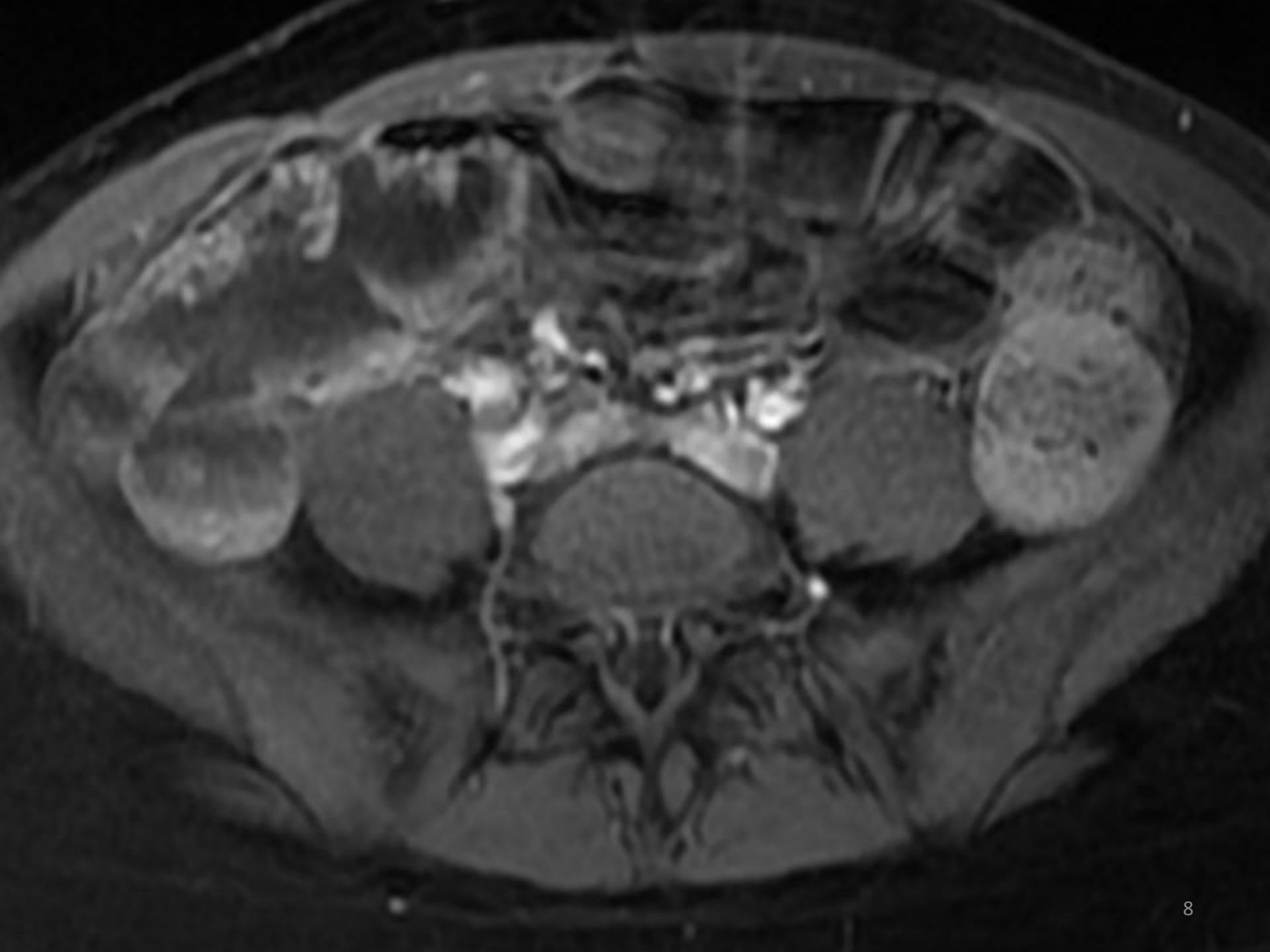23.3.2014

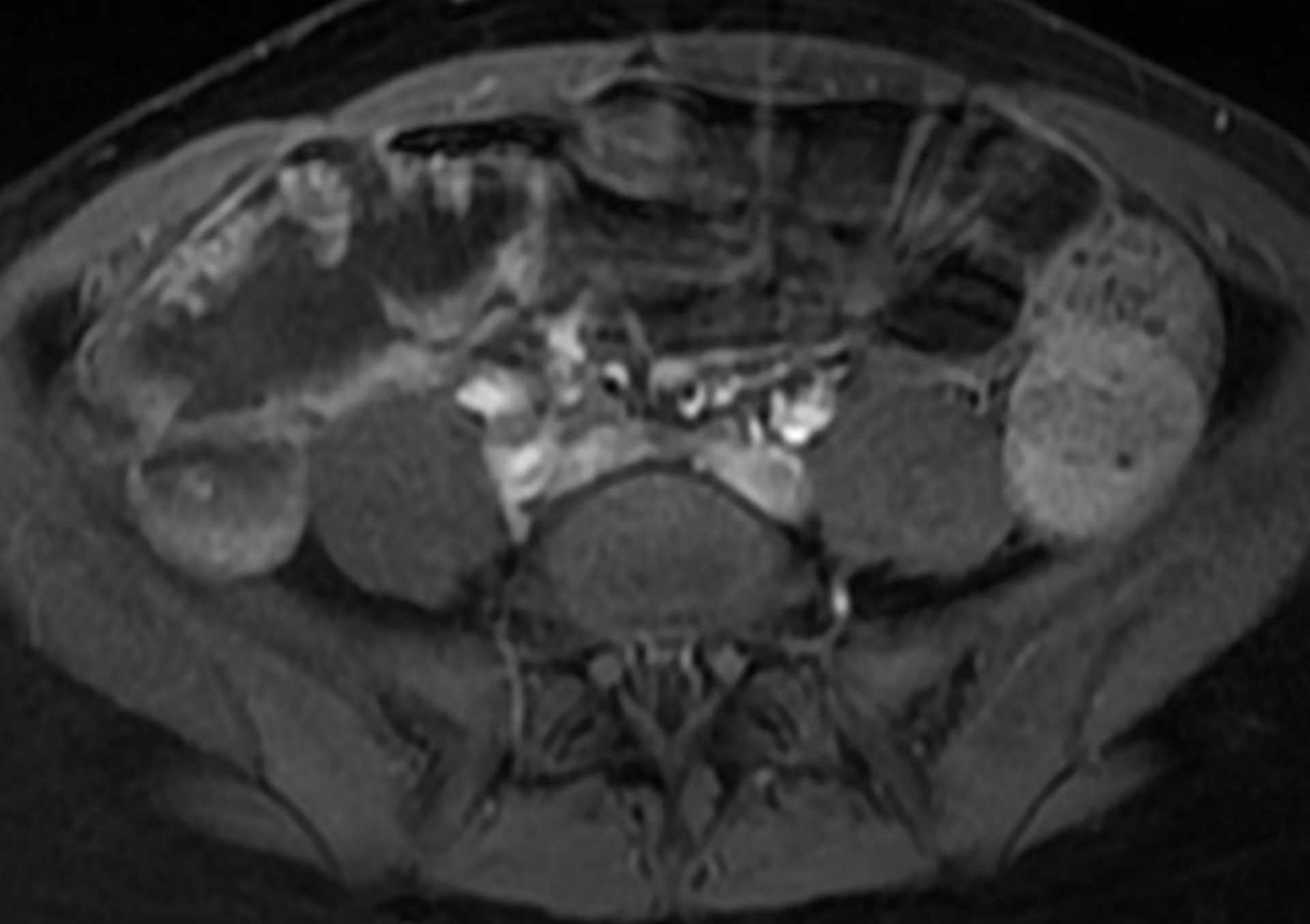


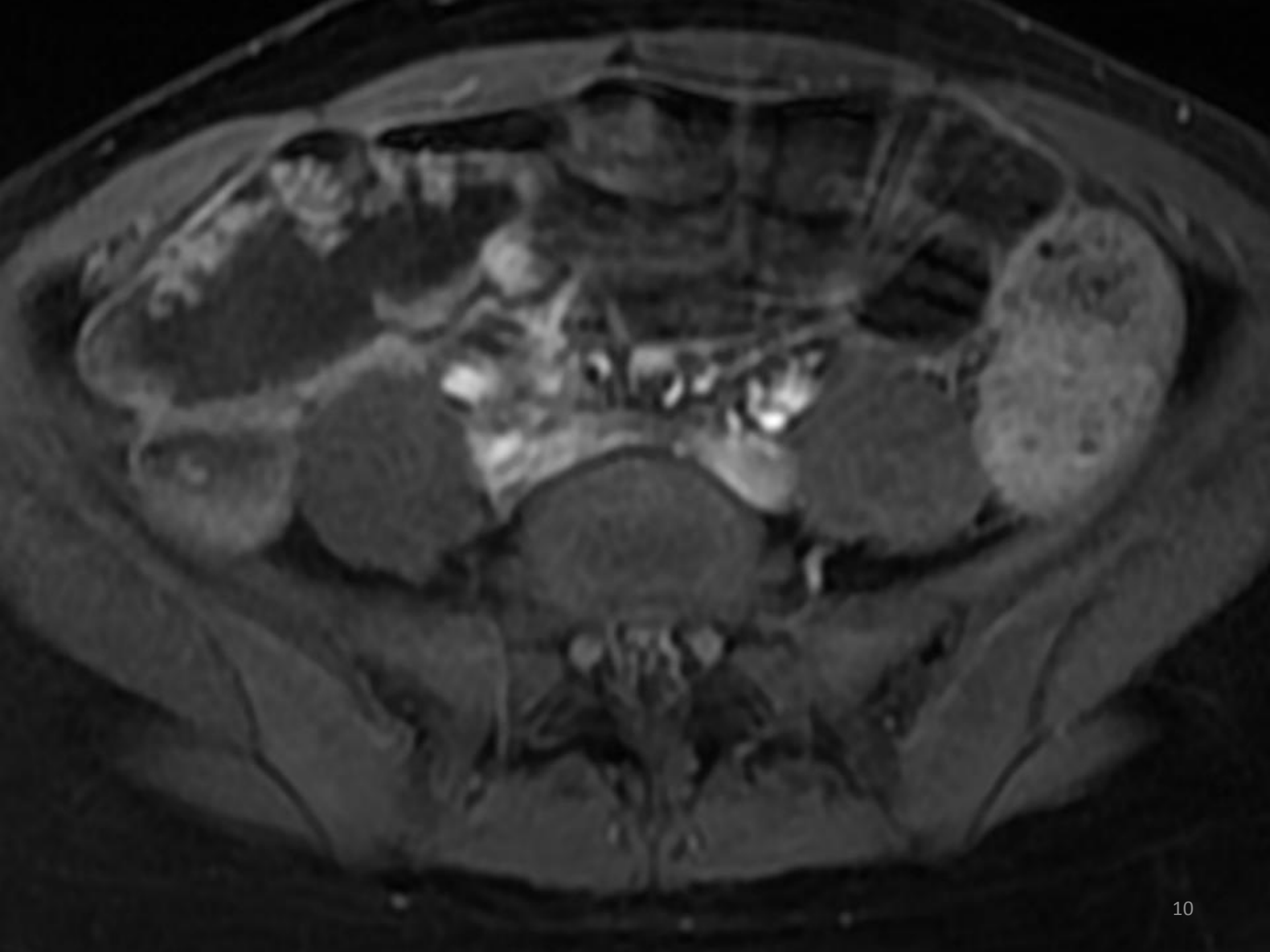
**T1 - pre injection with
fat suppression**

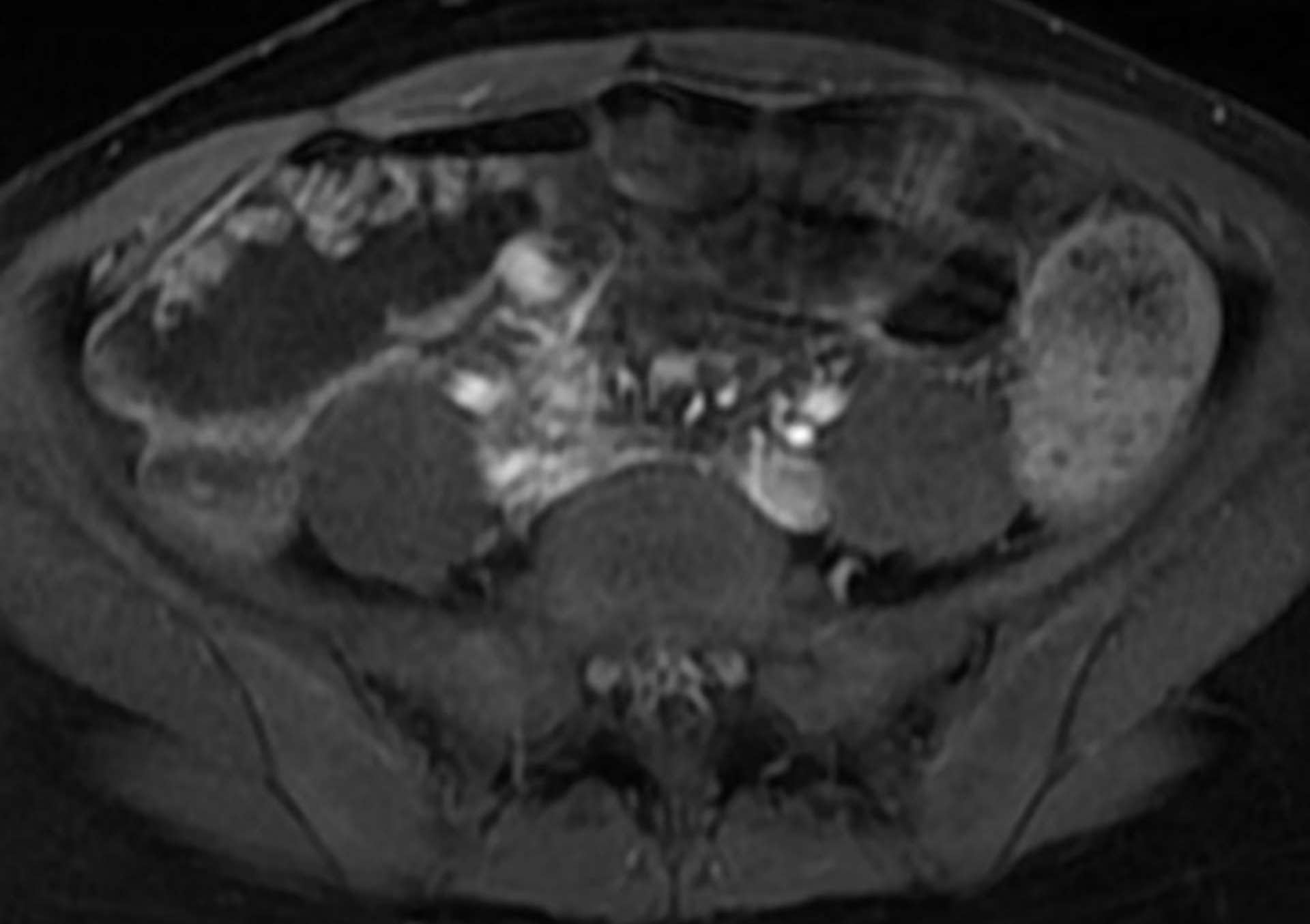
**T1 - post injection with
fat suppression**

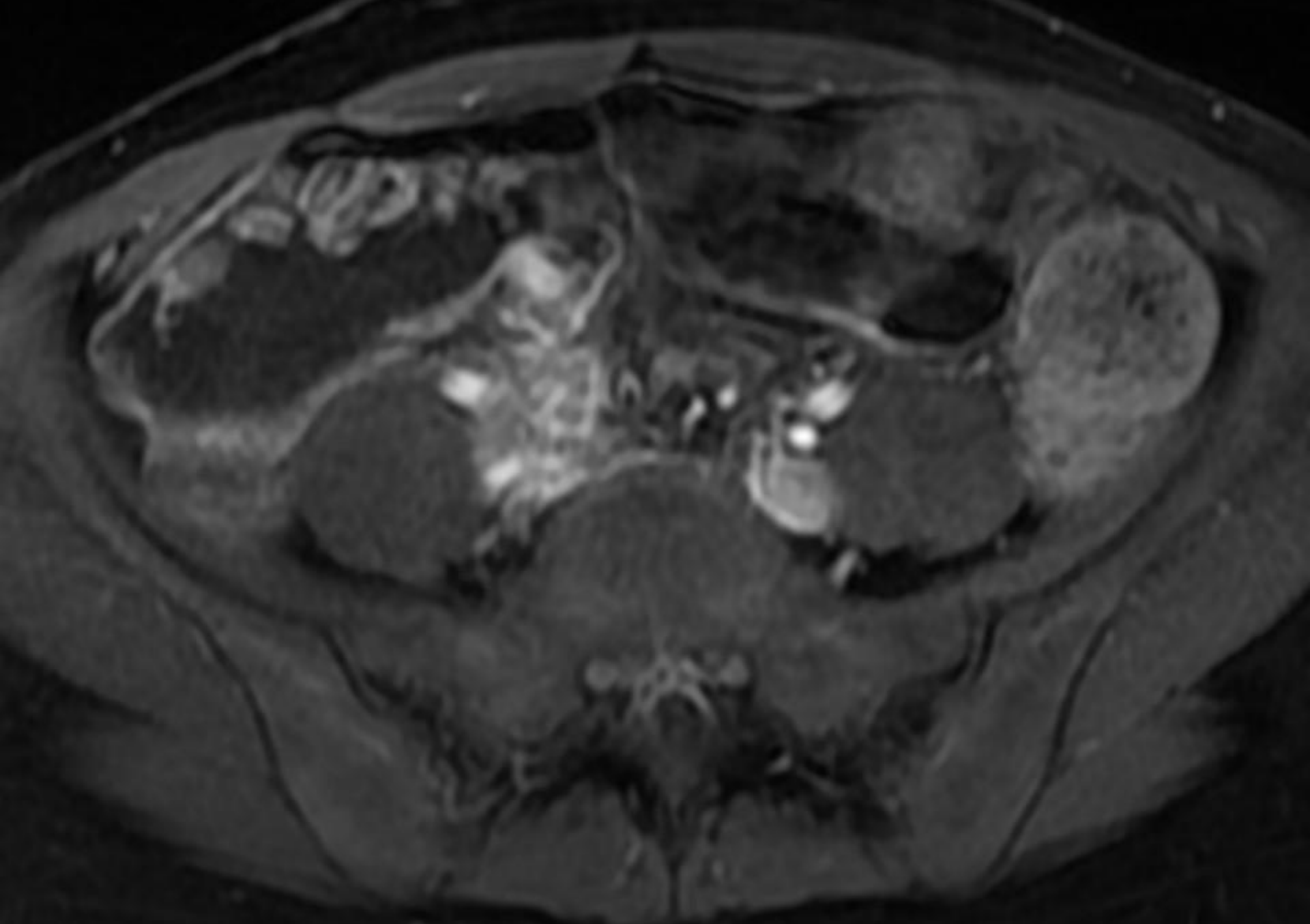


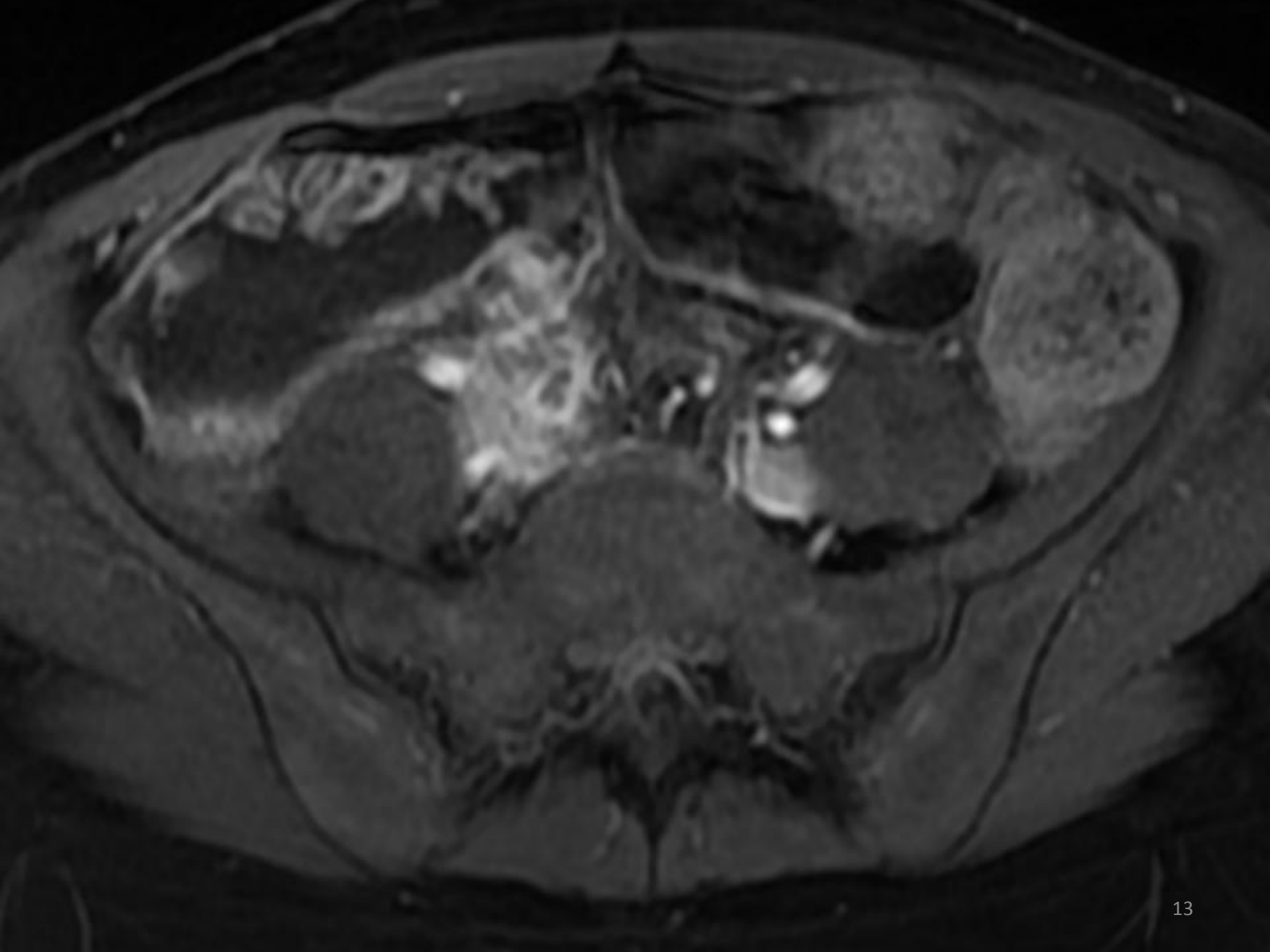


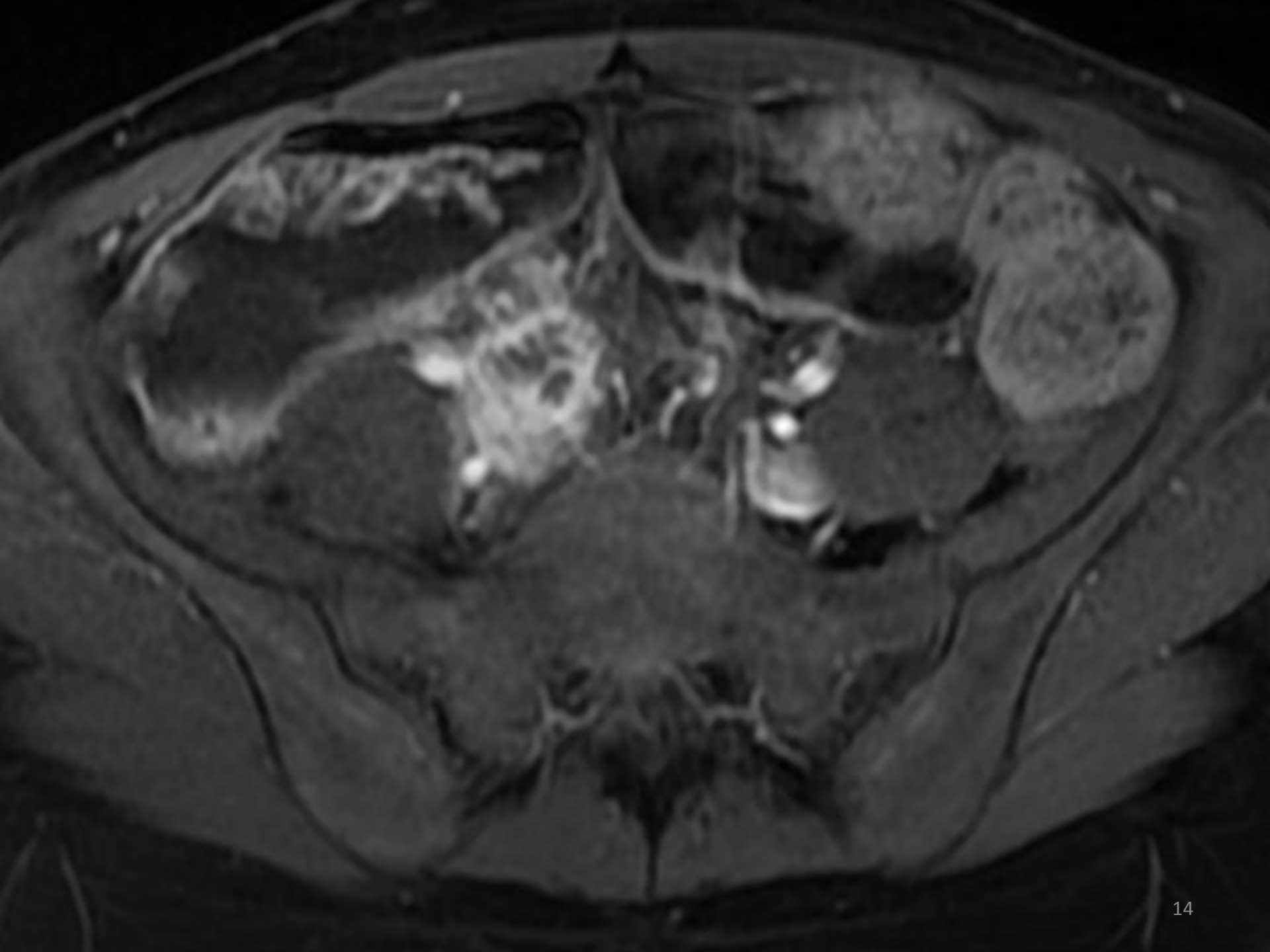


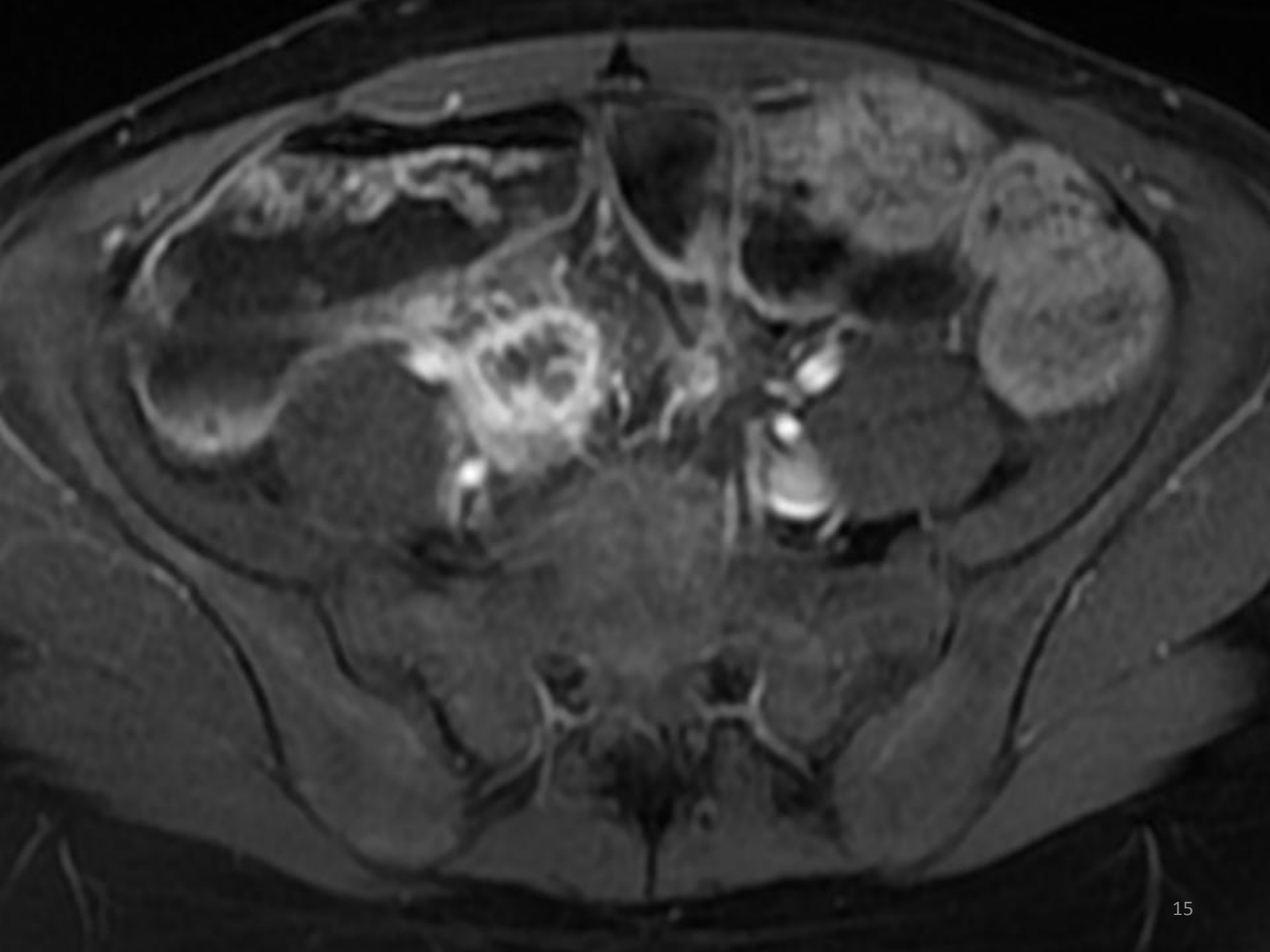


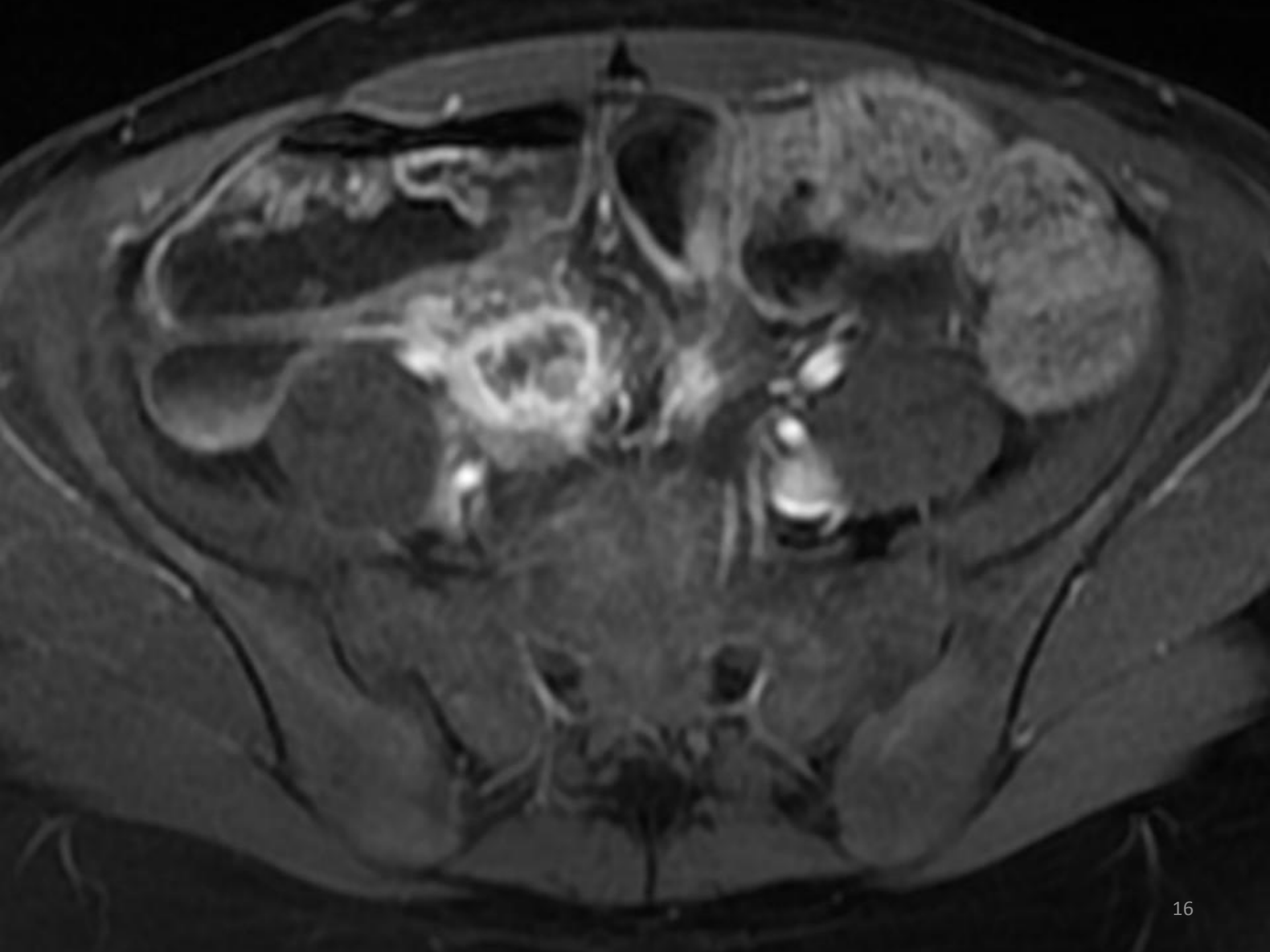


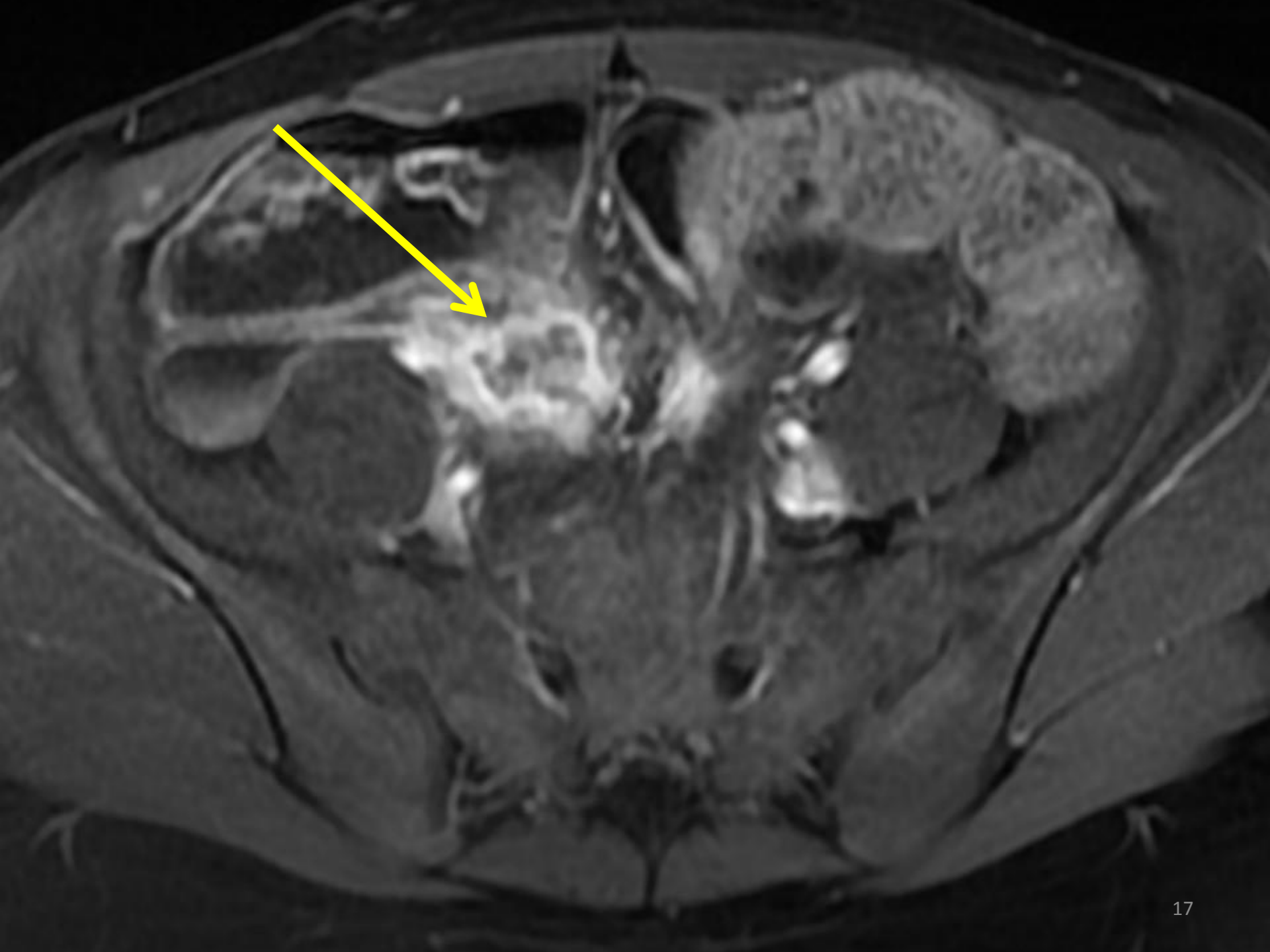


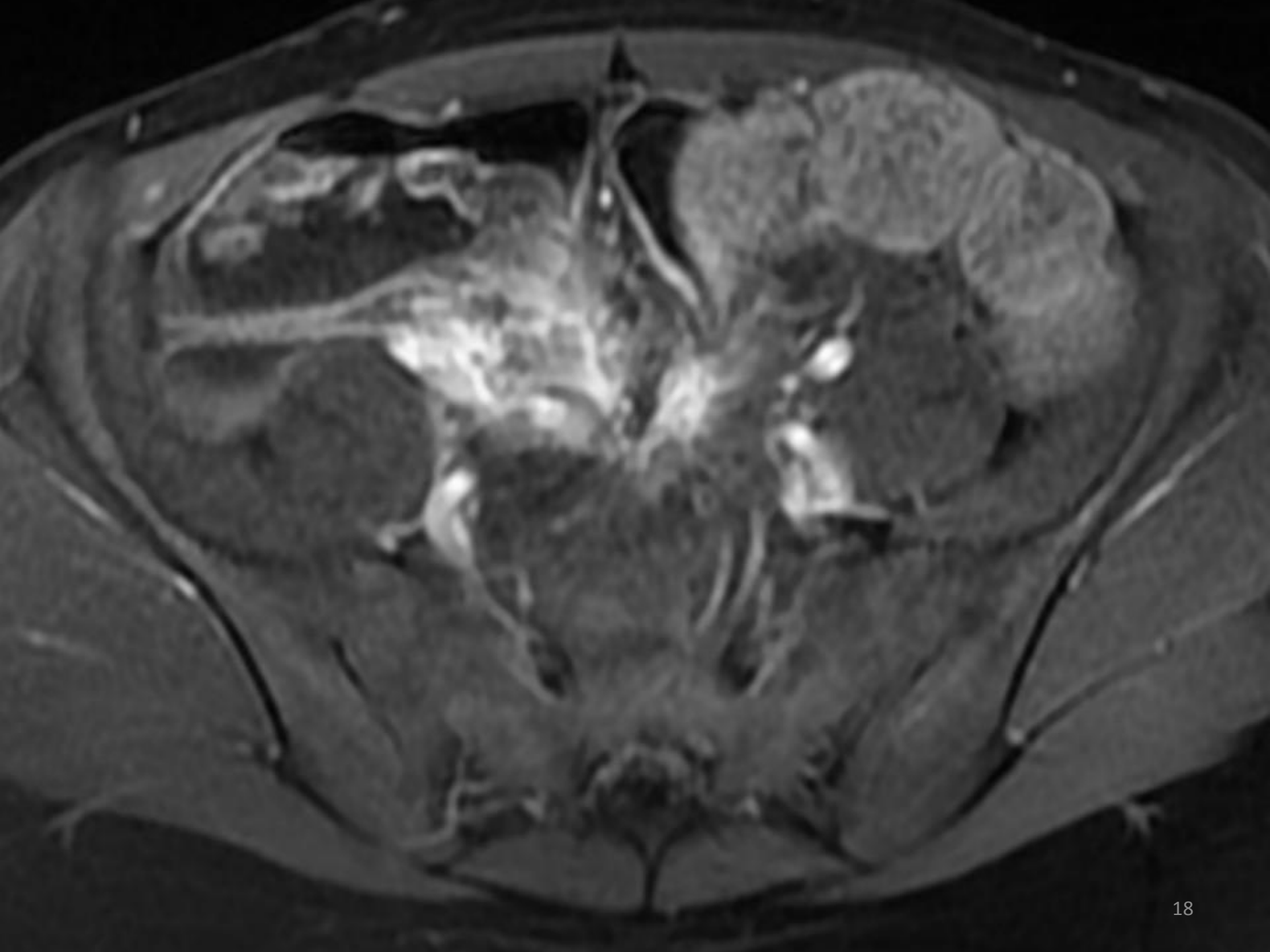


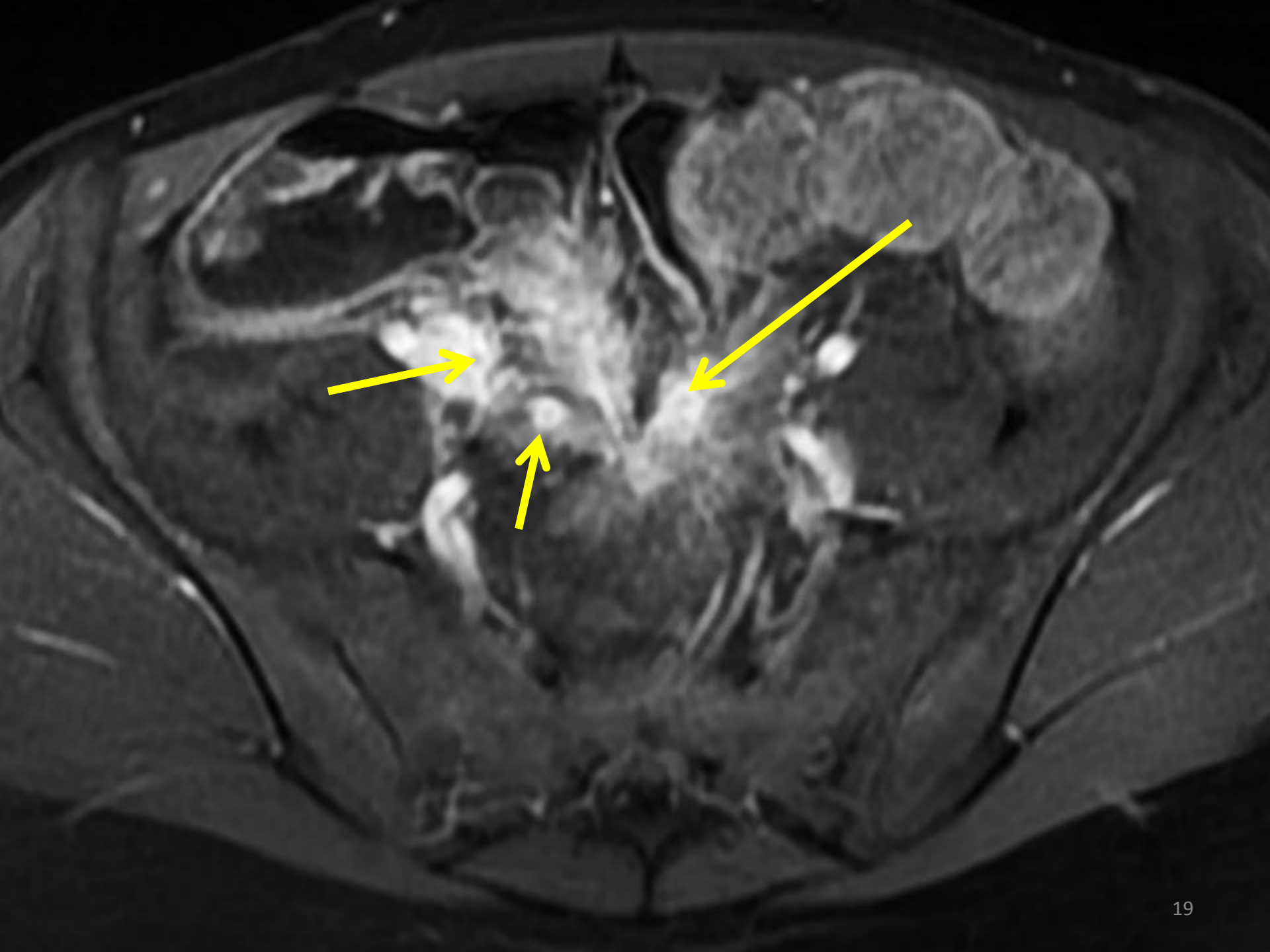


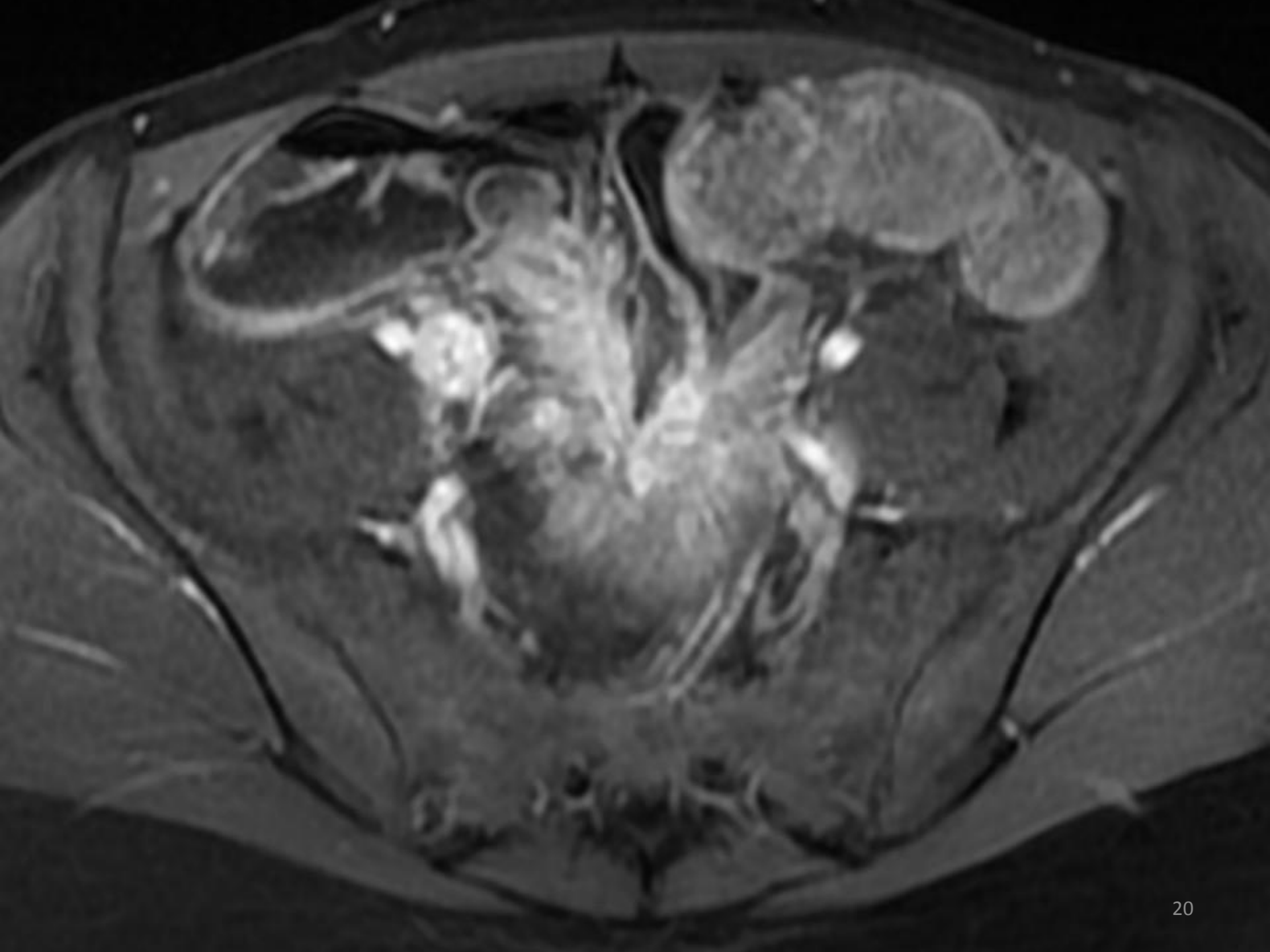


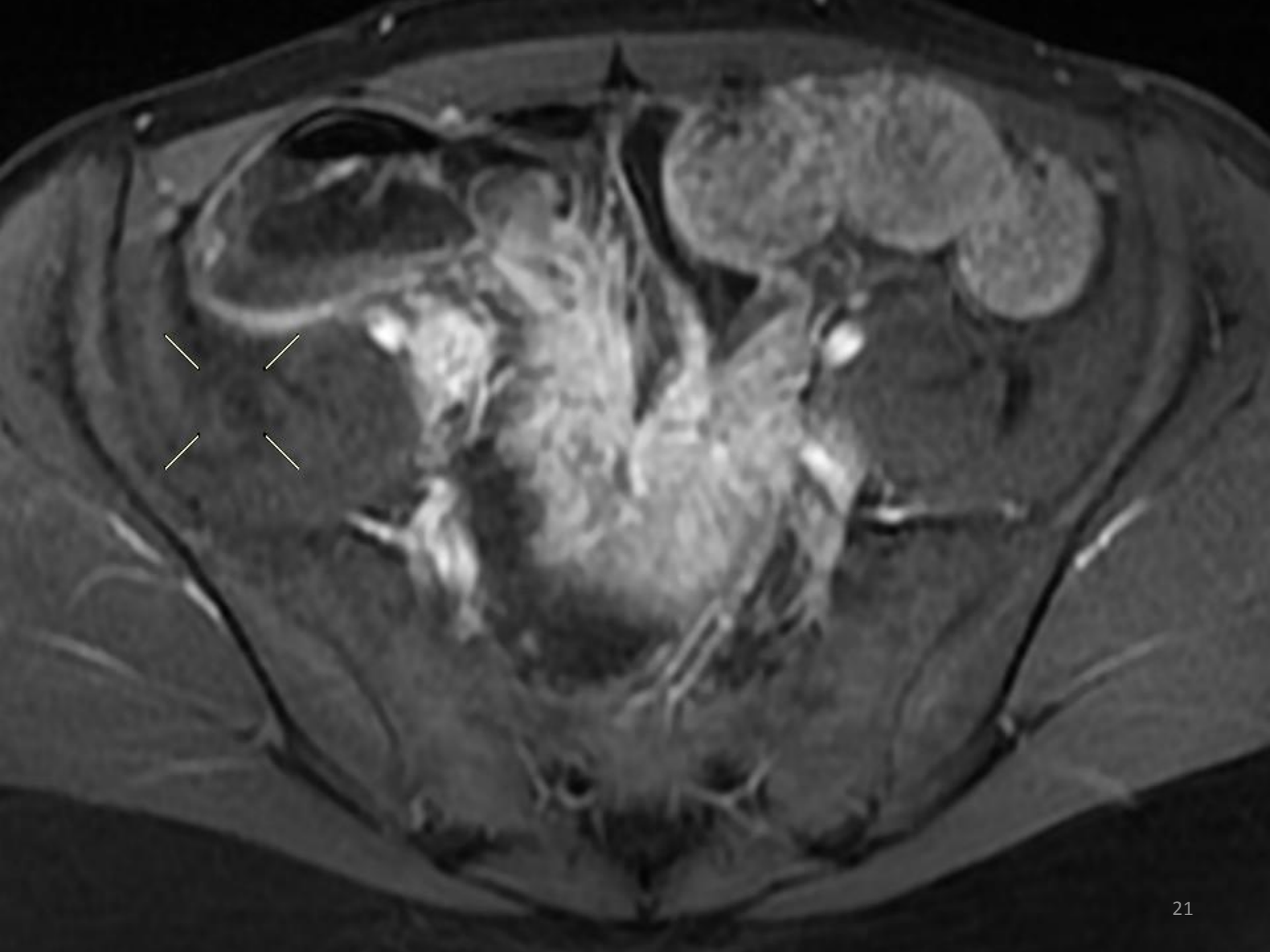


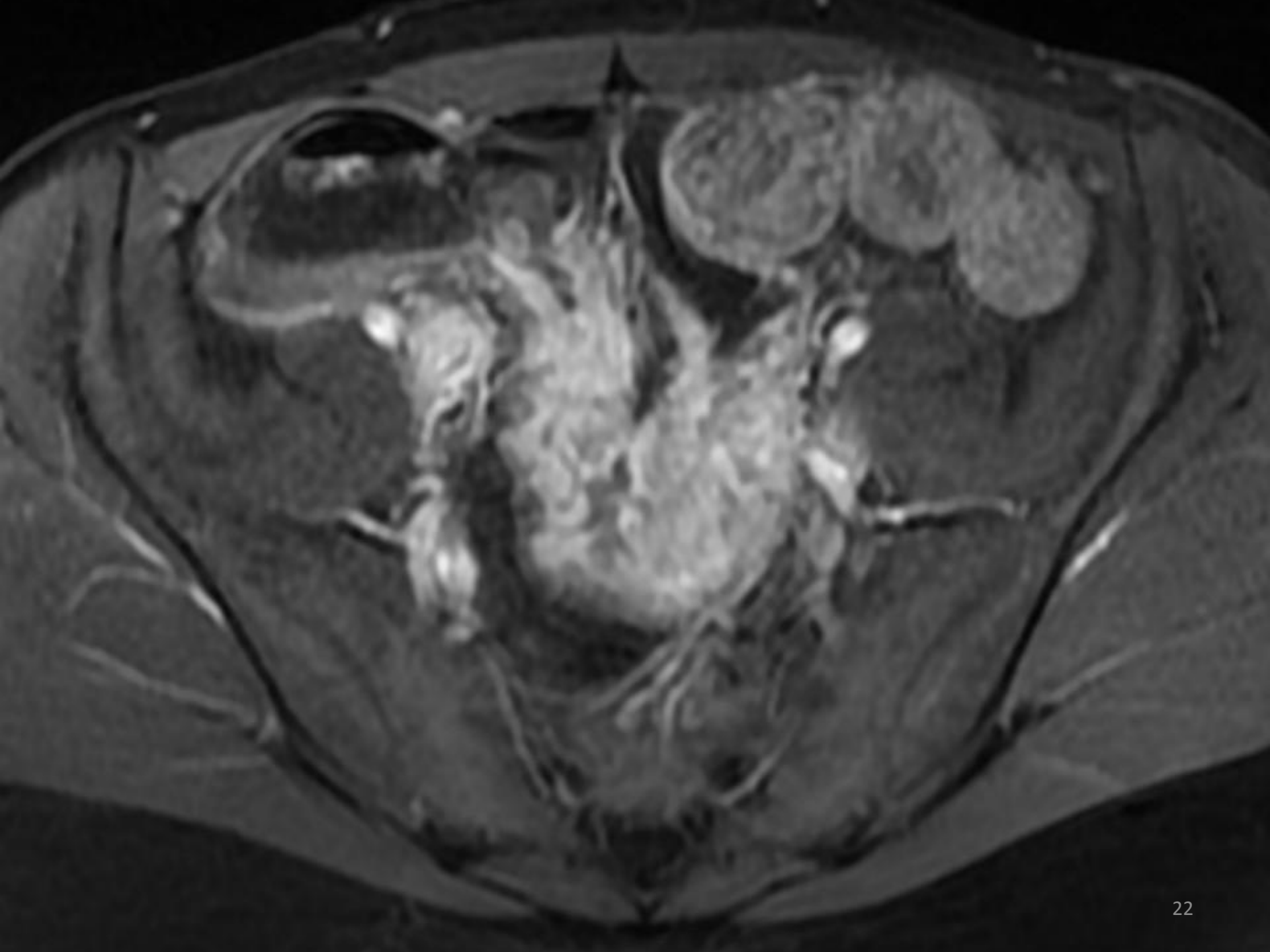


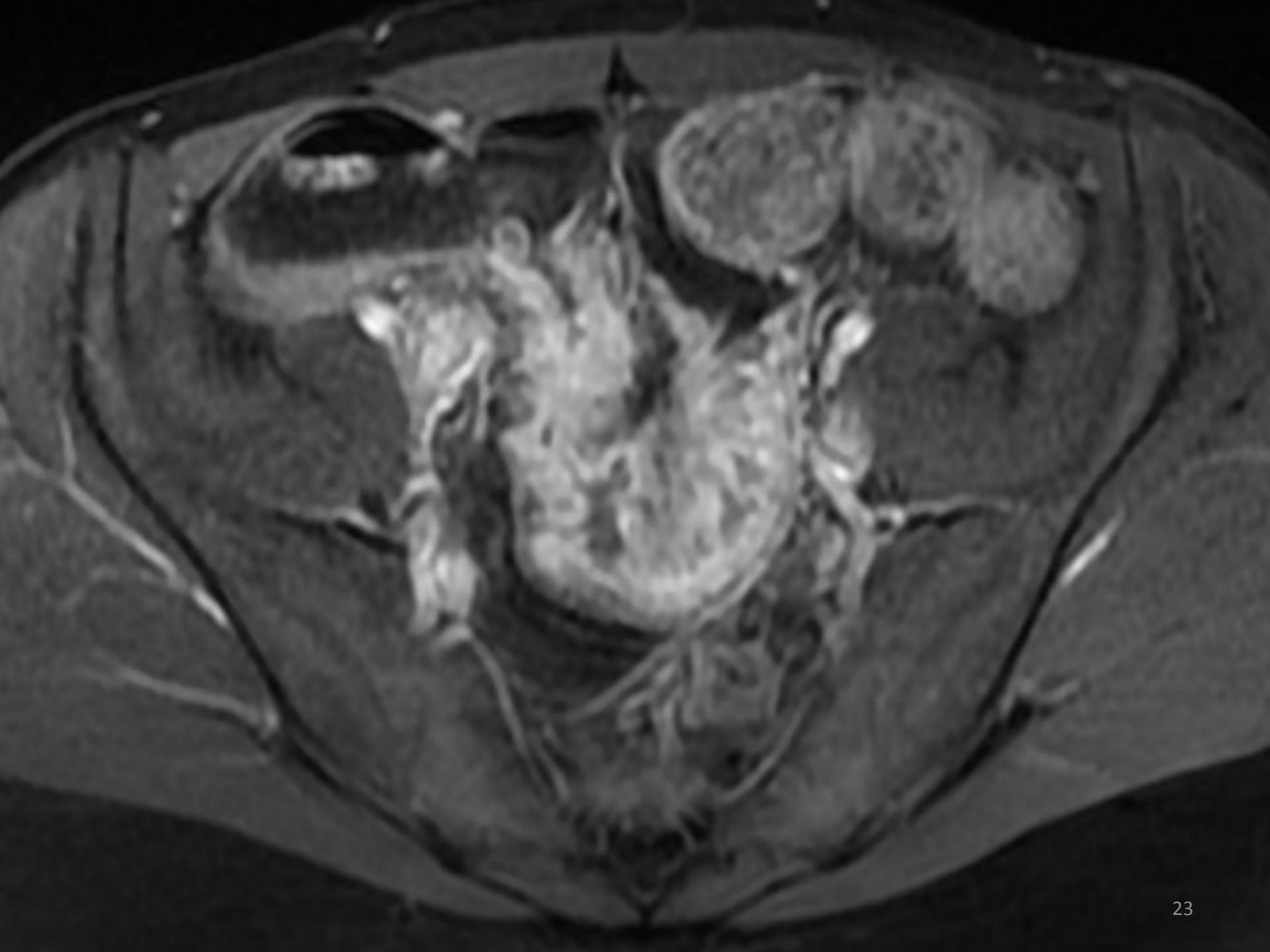


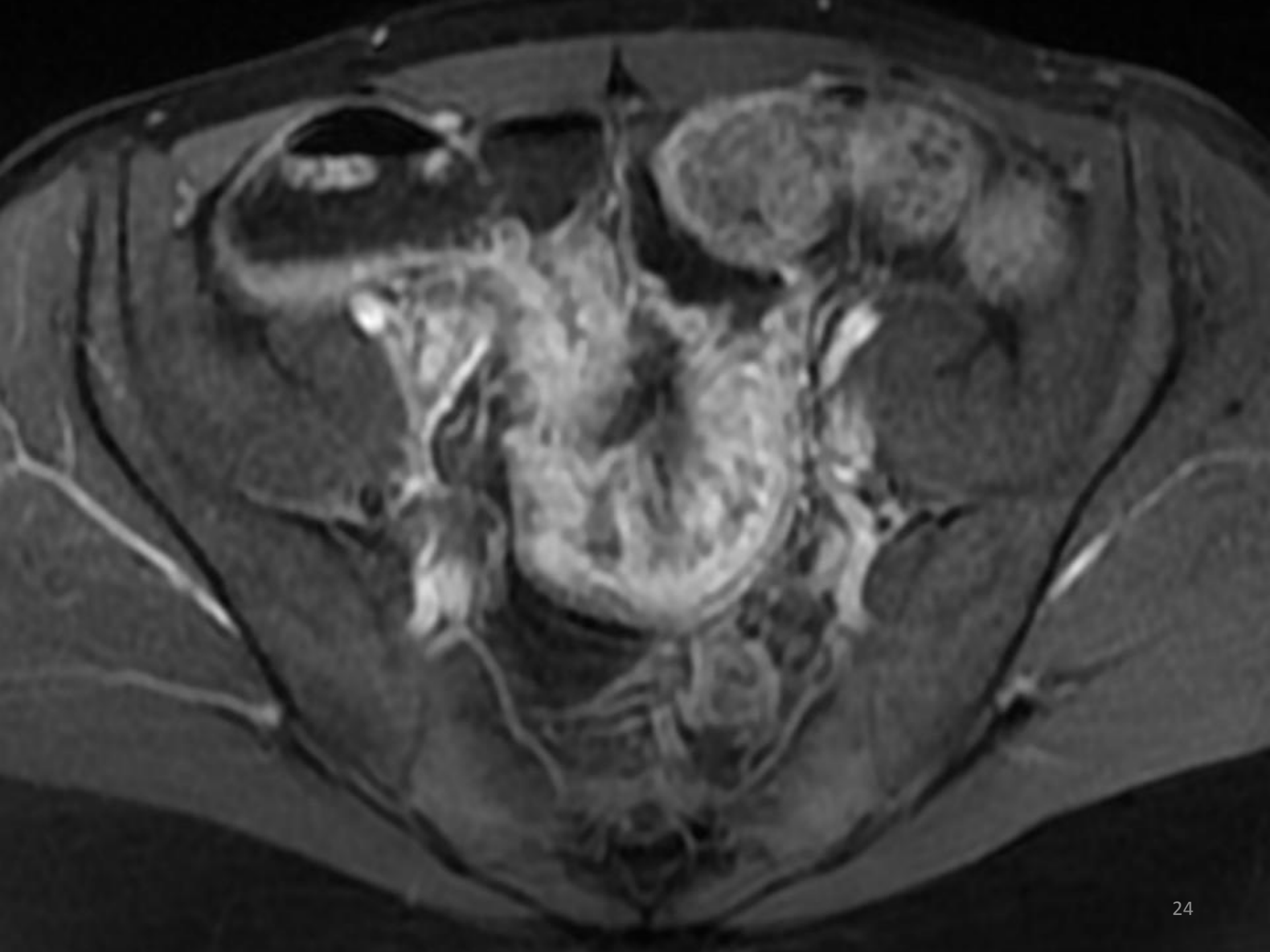


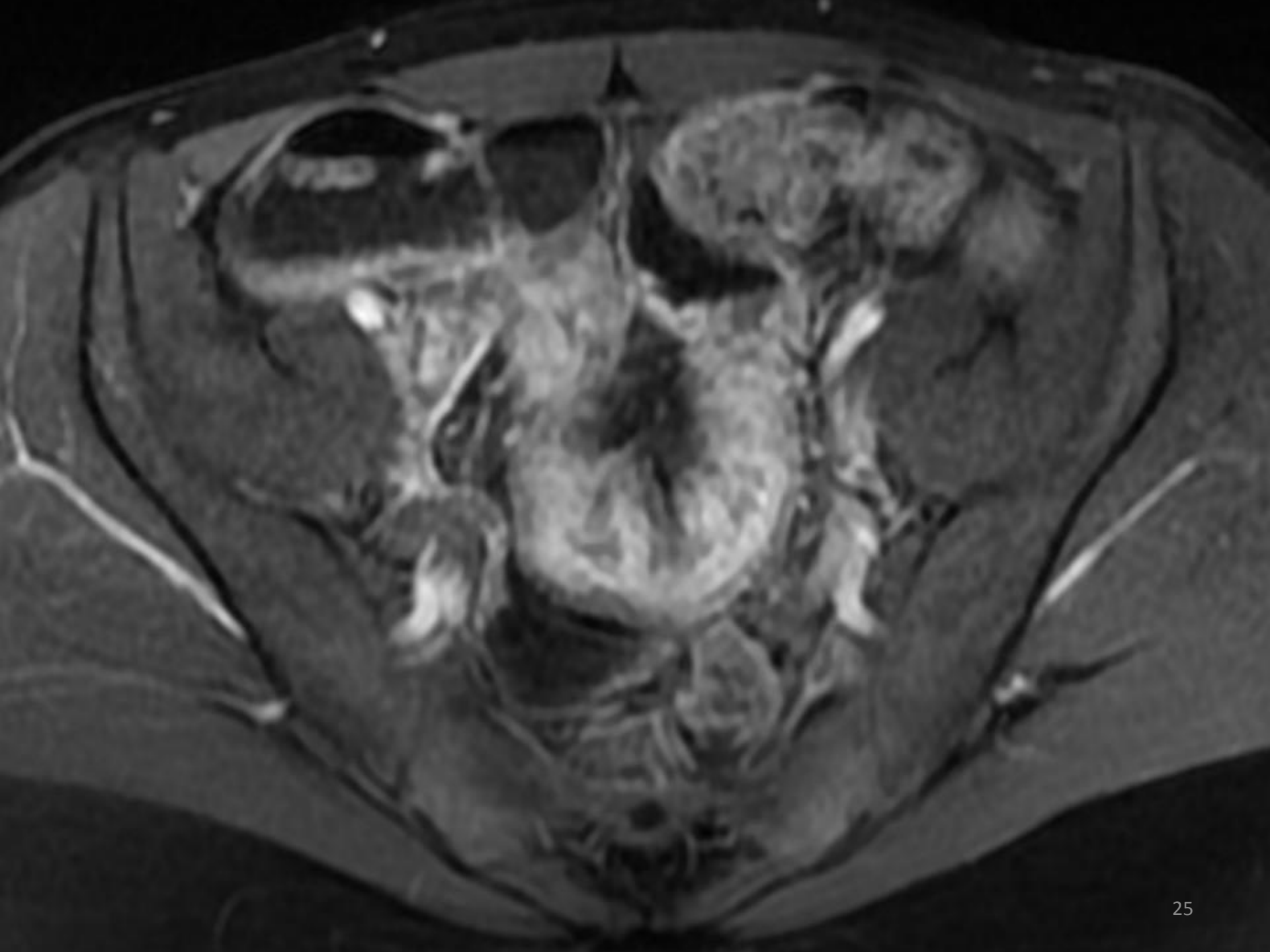


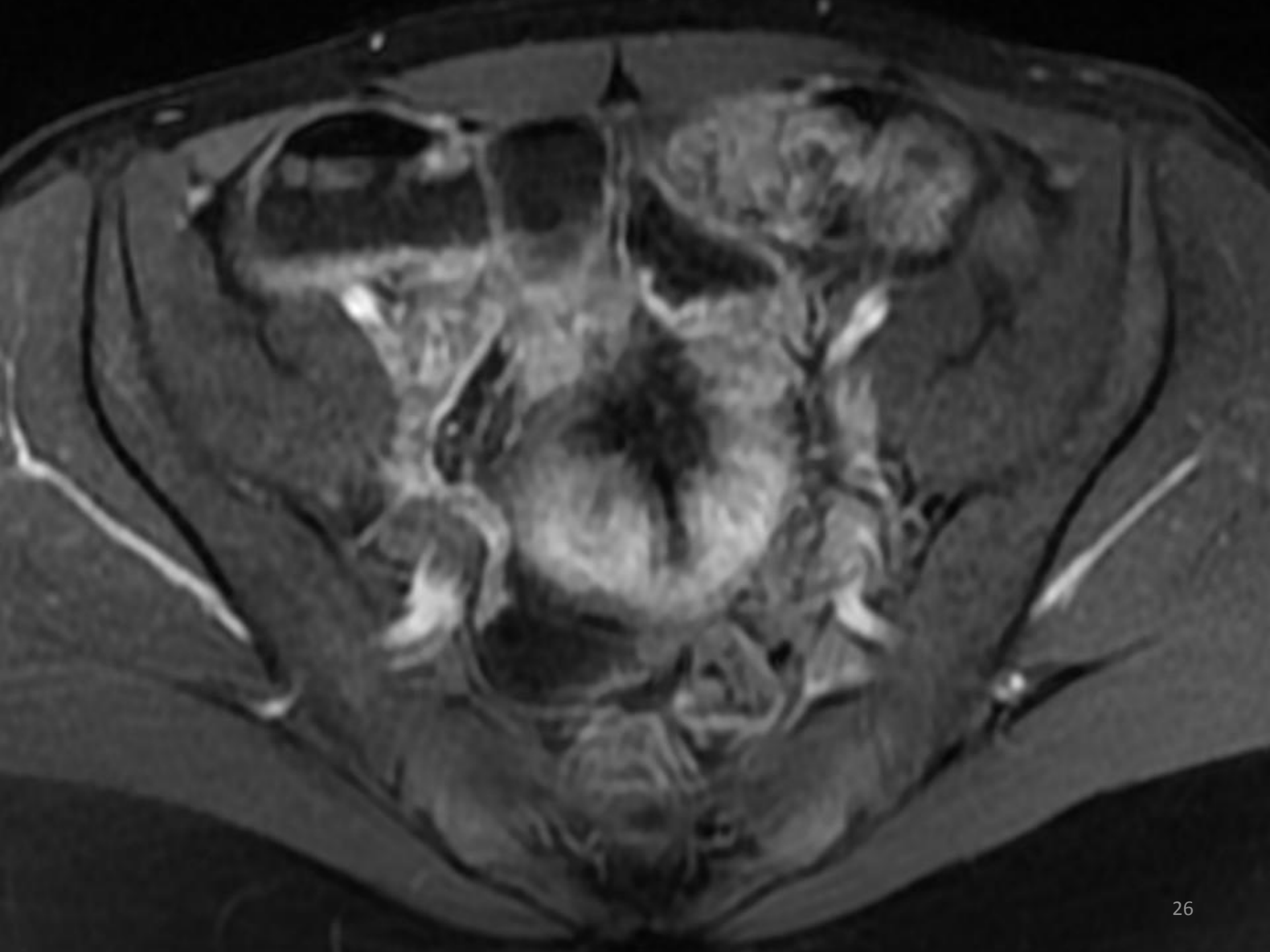


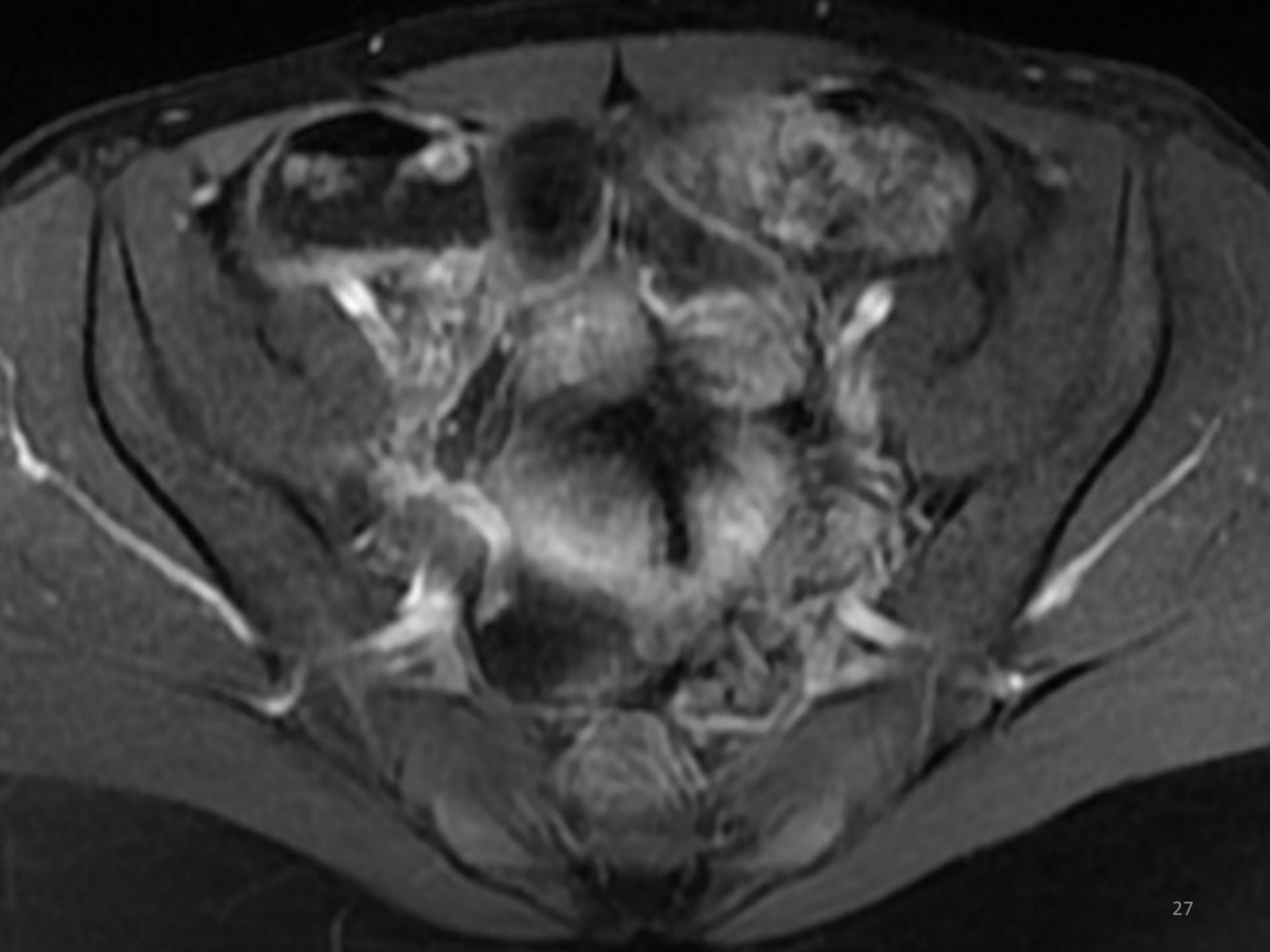


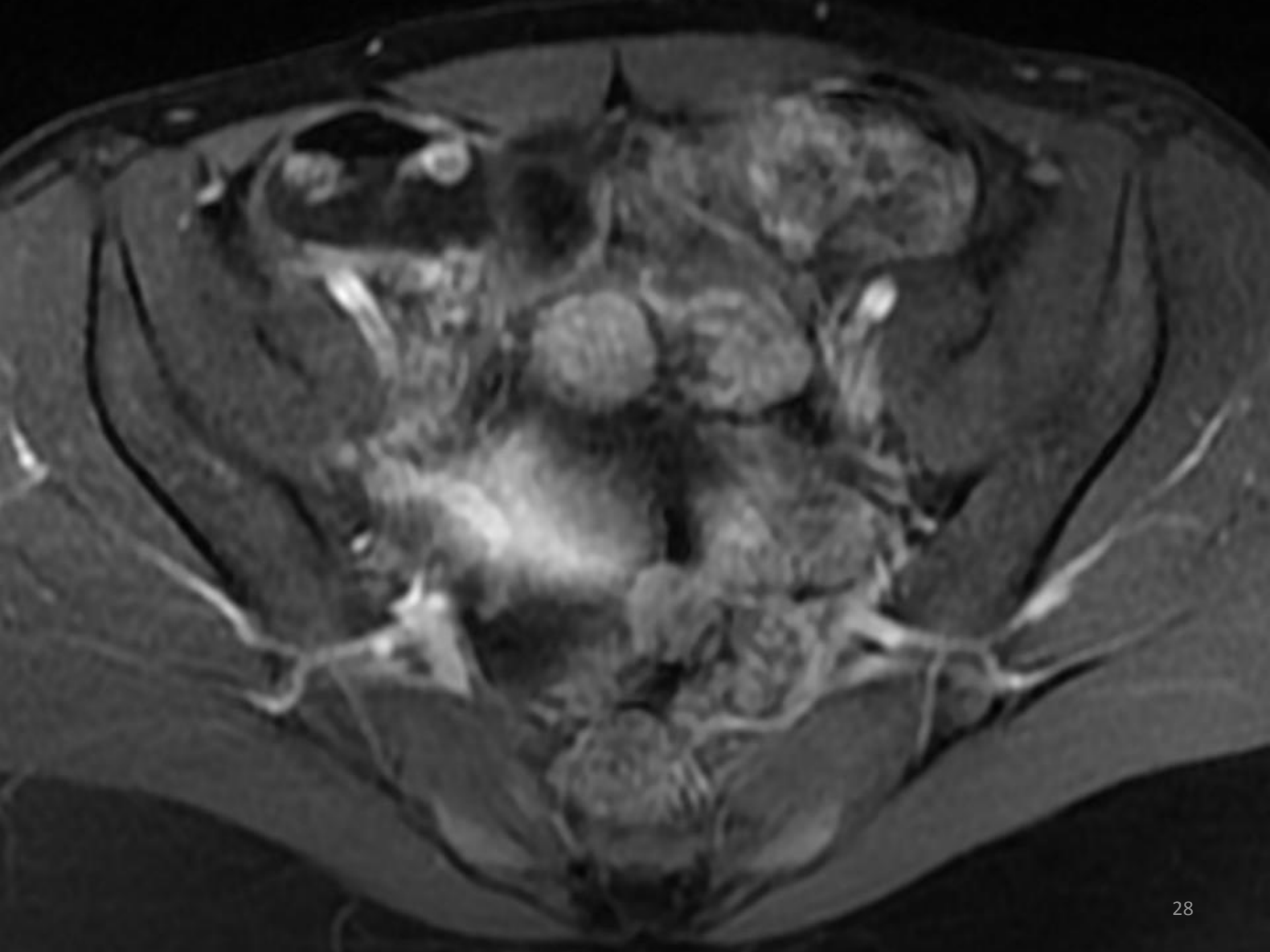


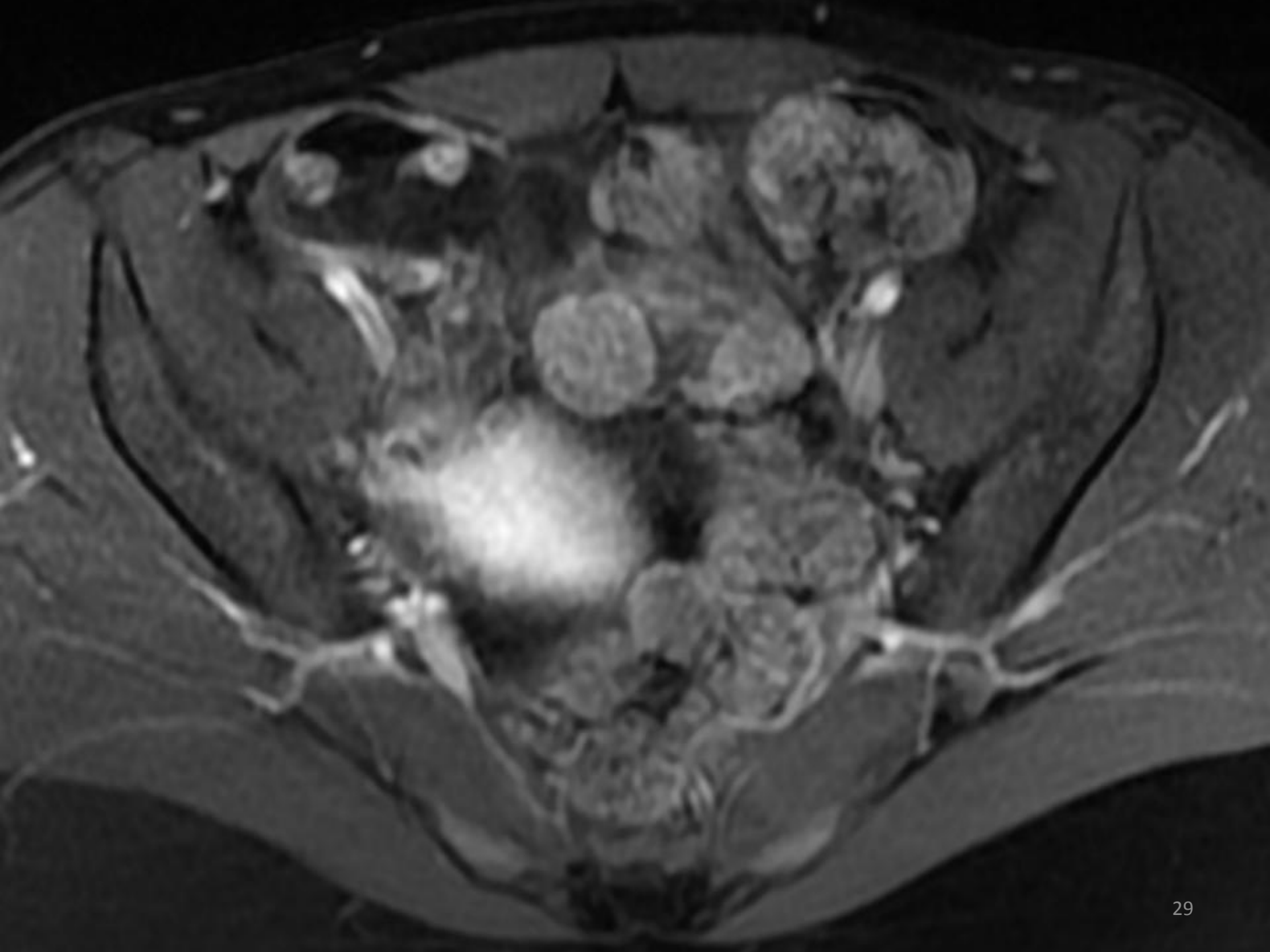


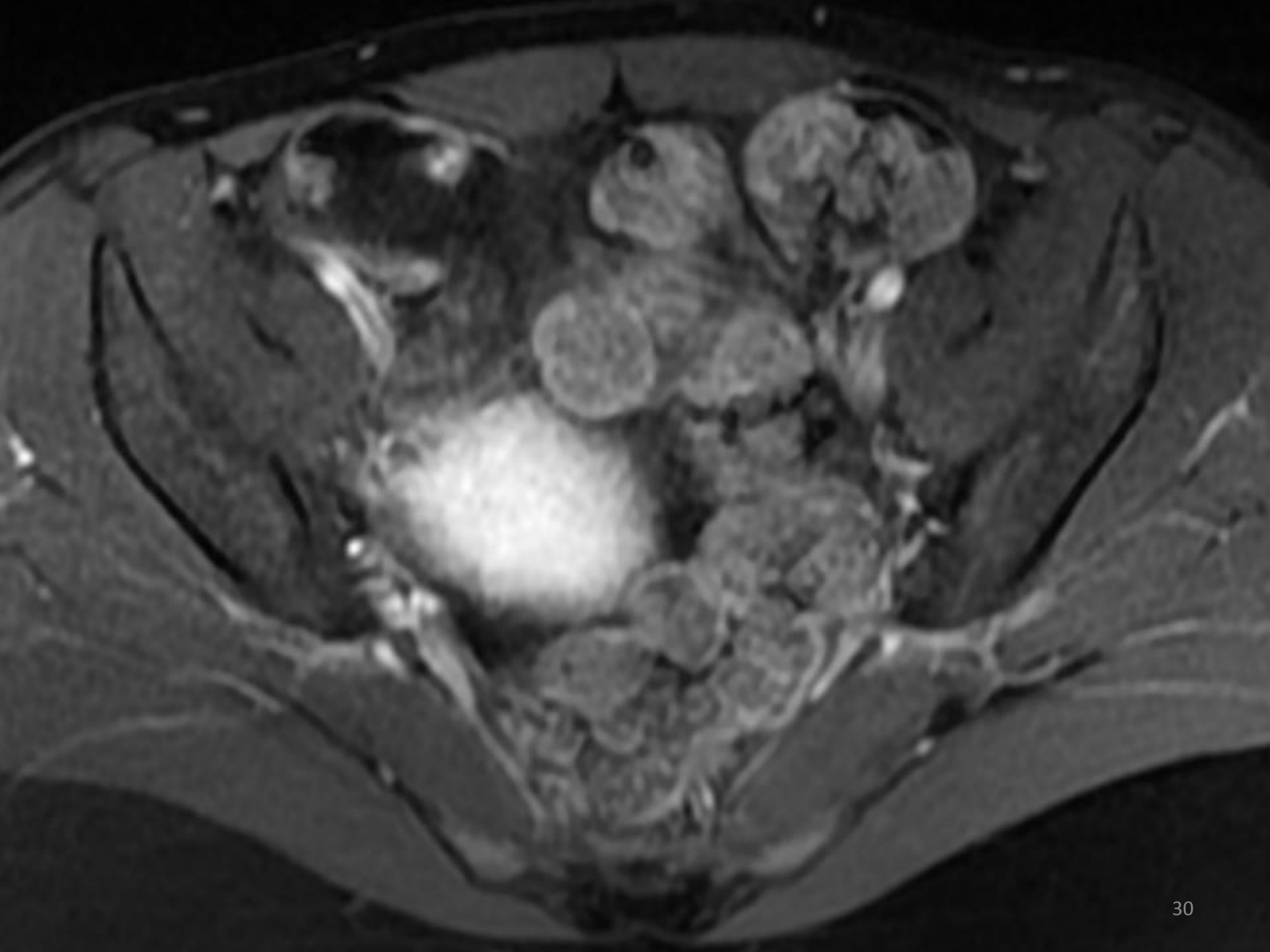


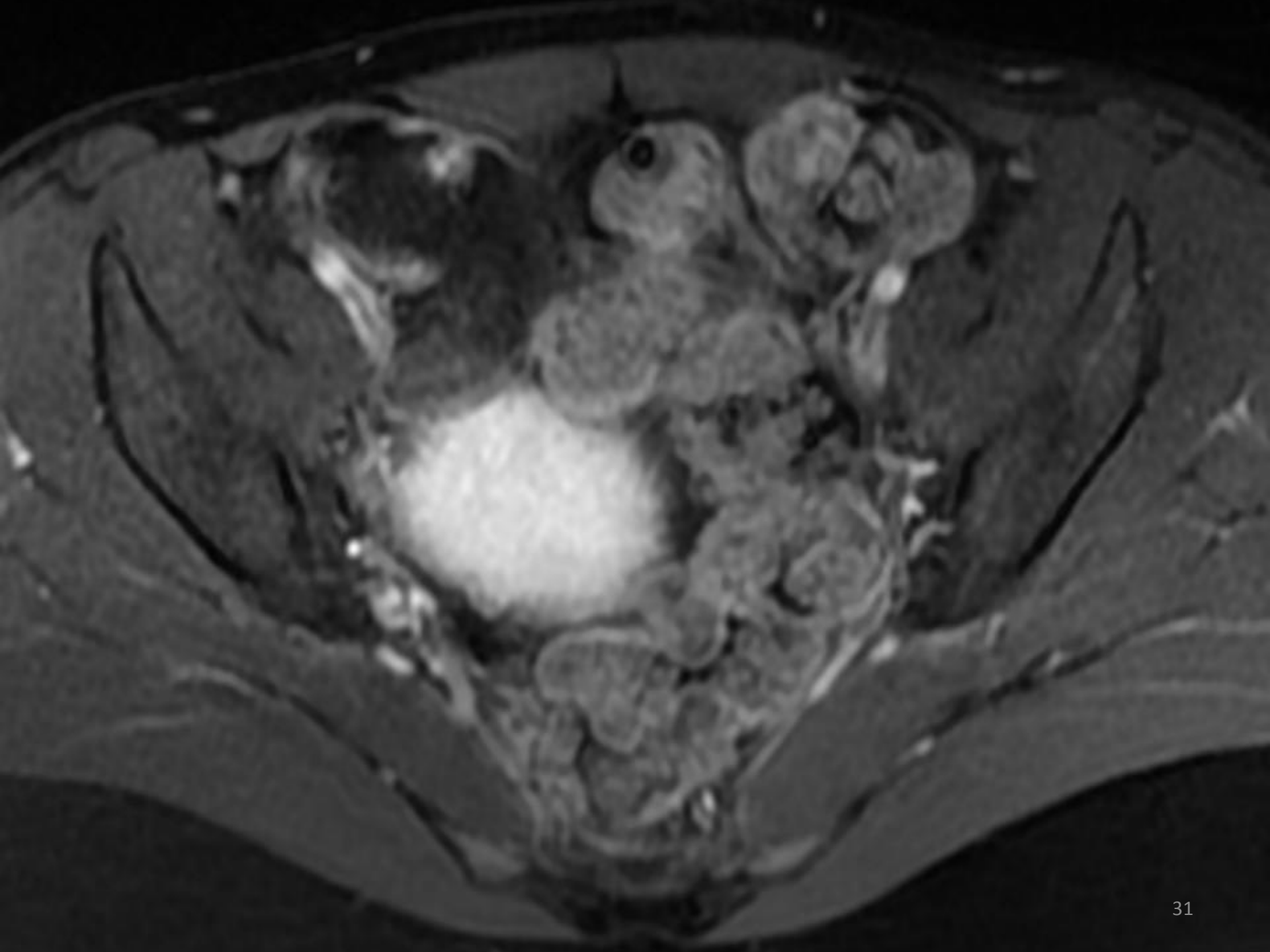


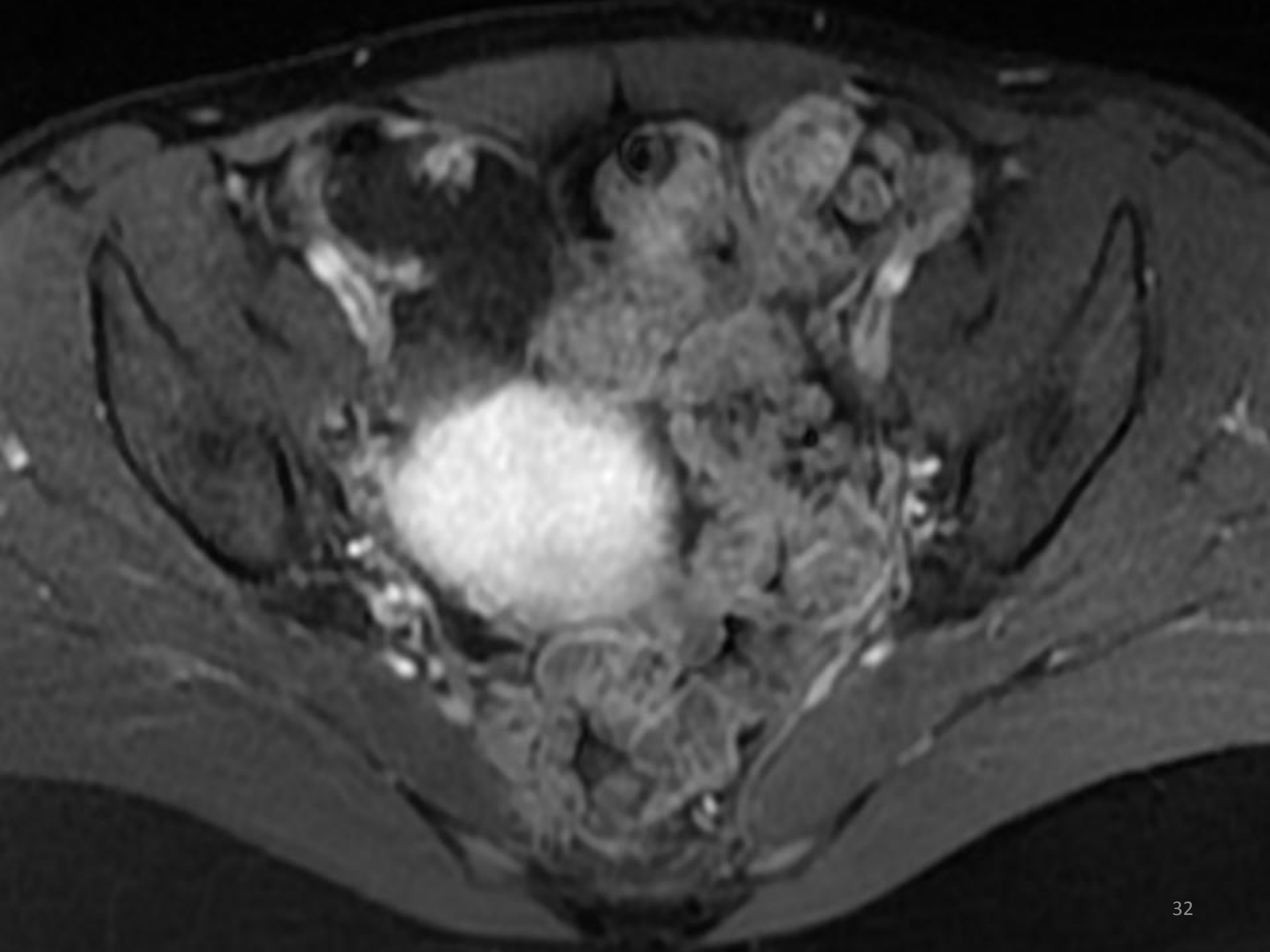


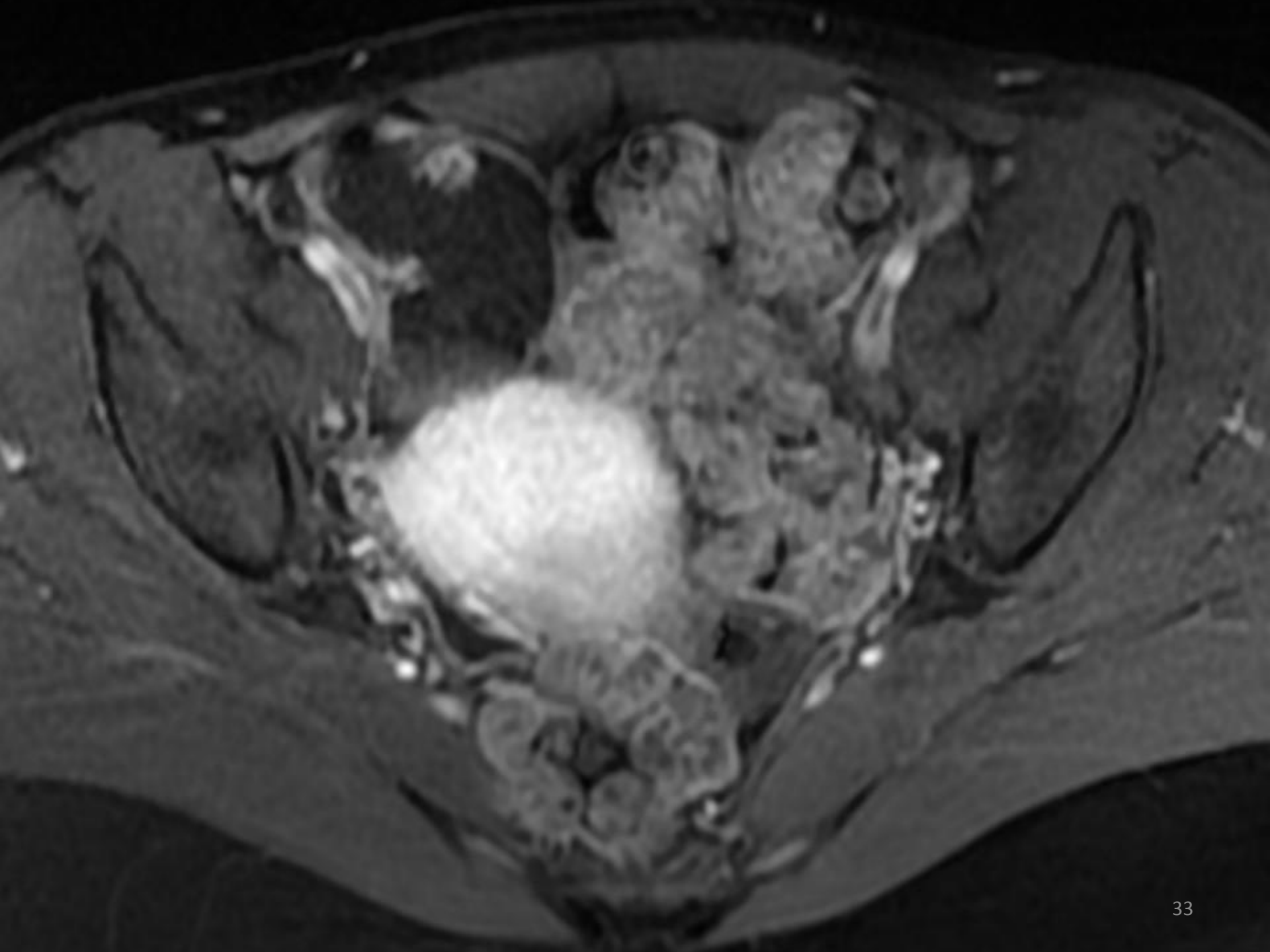


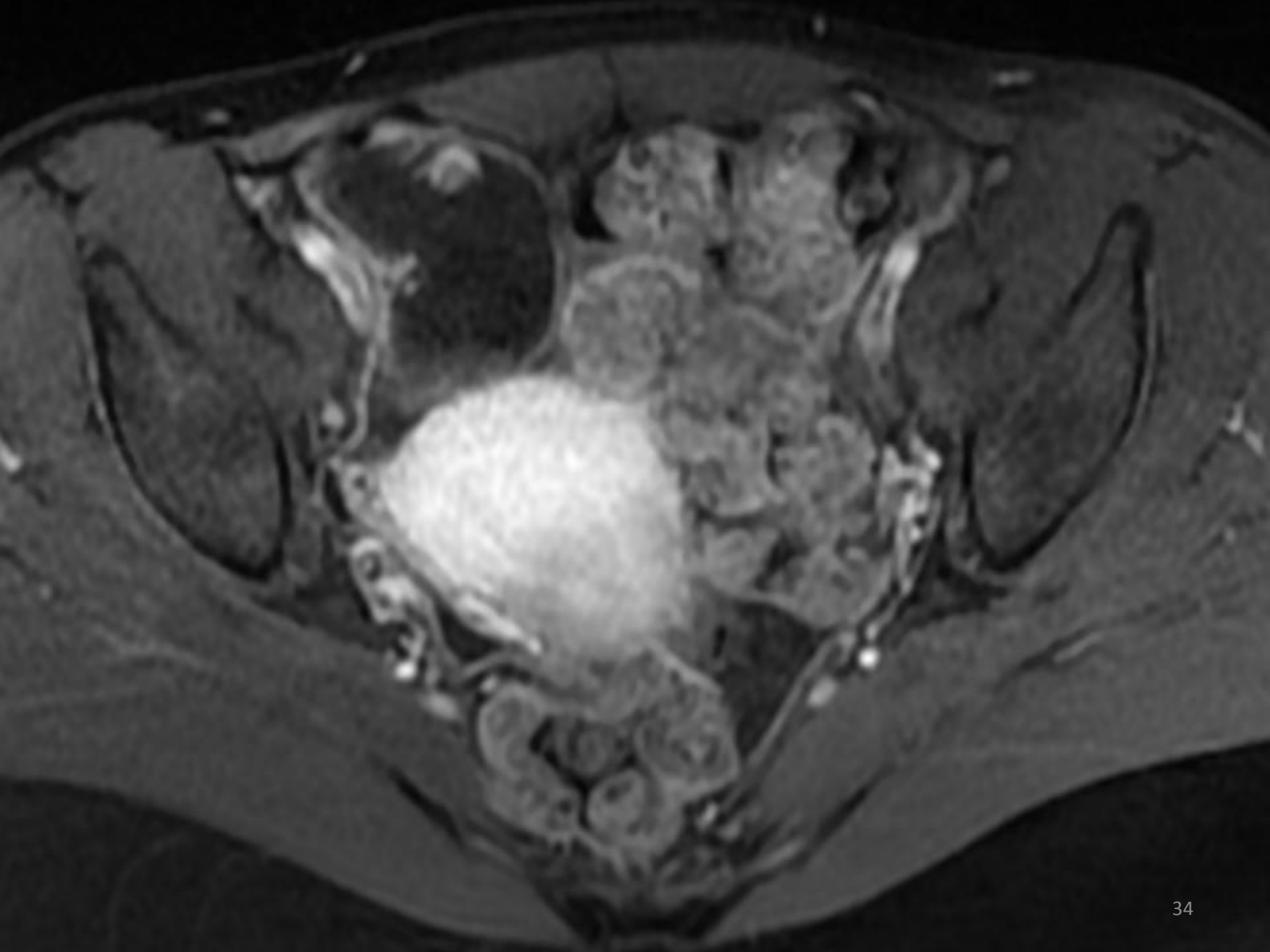


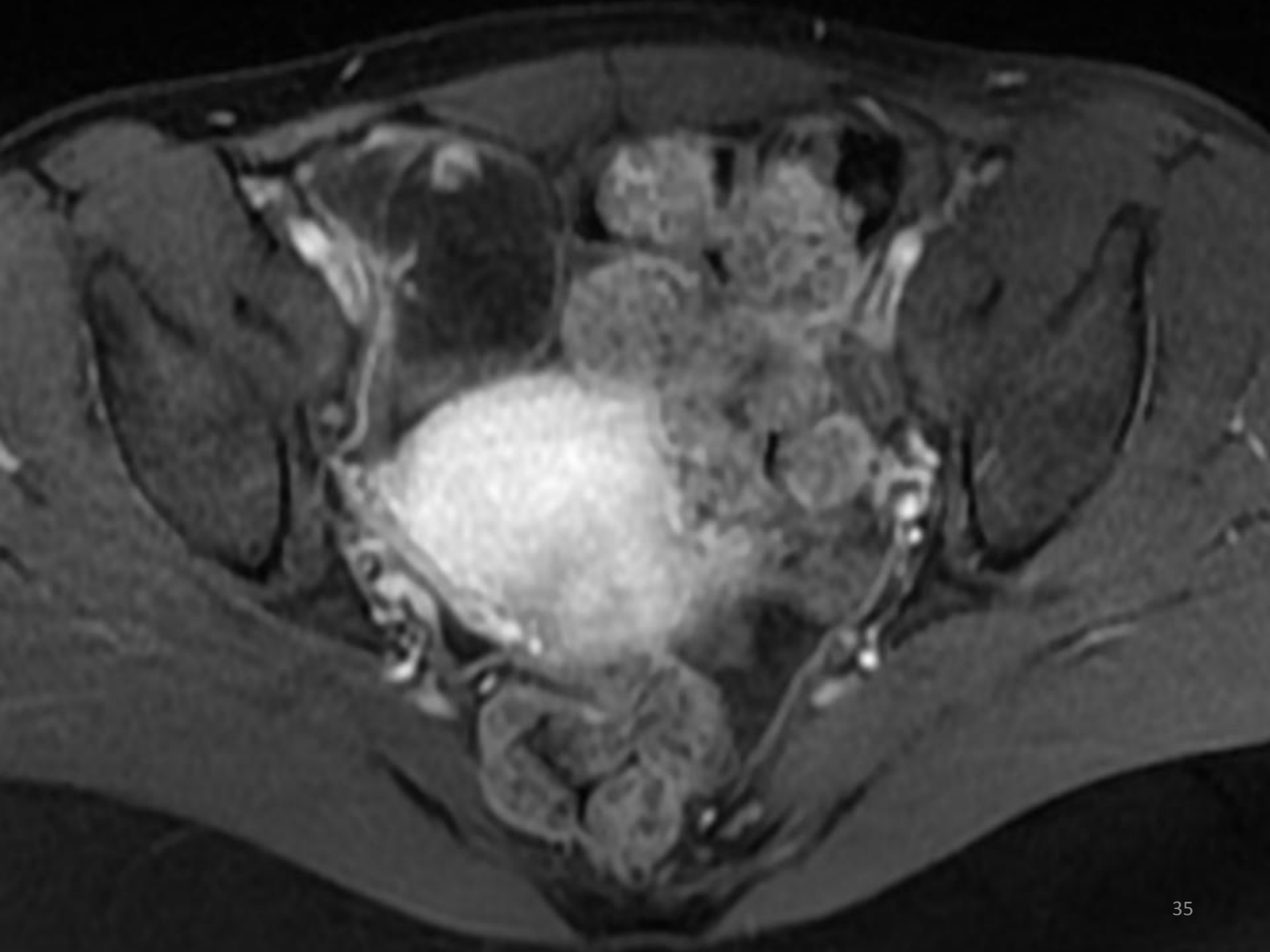


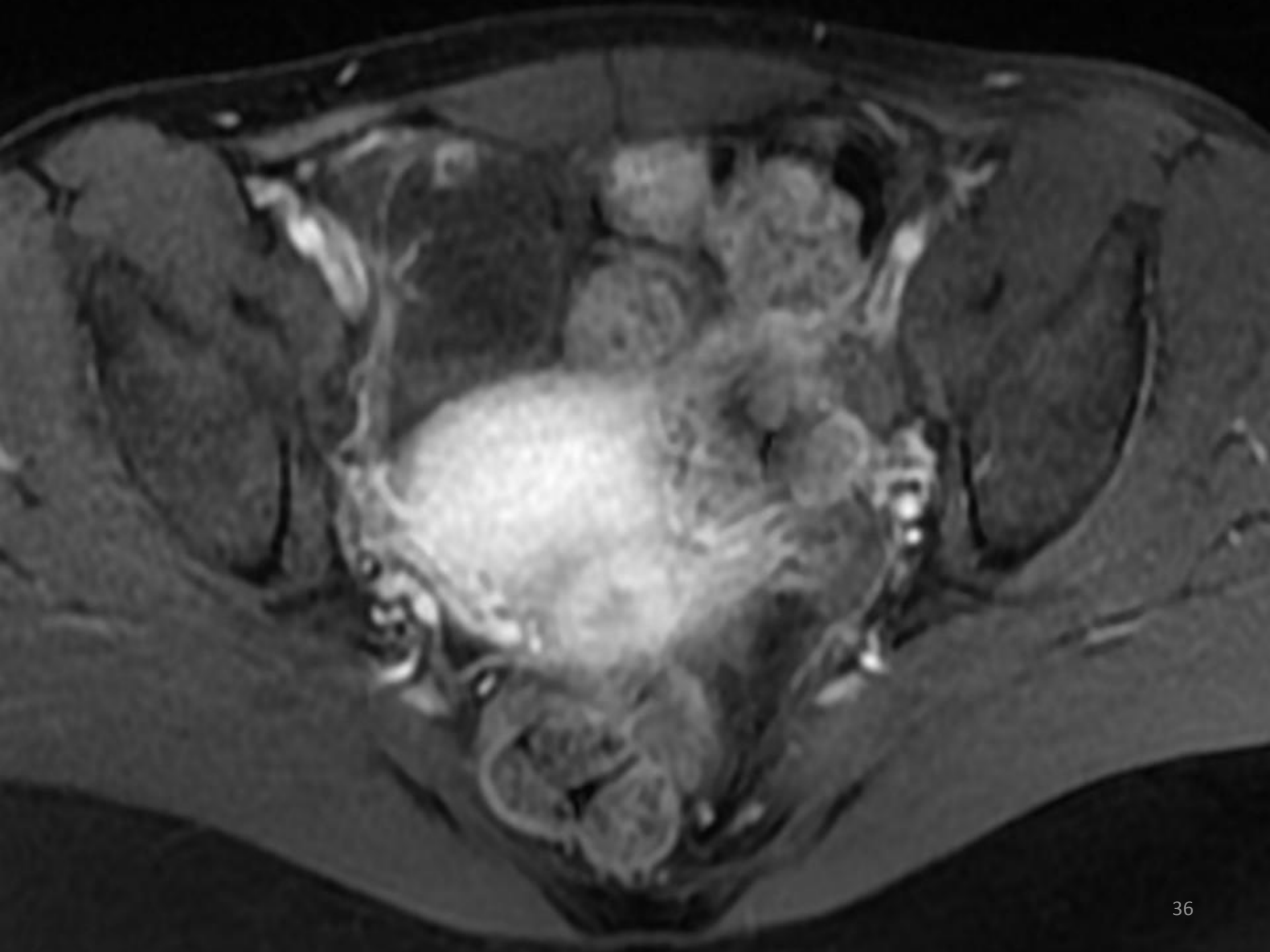


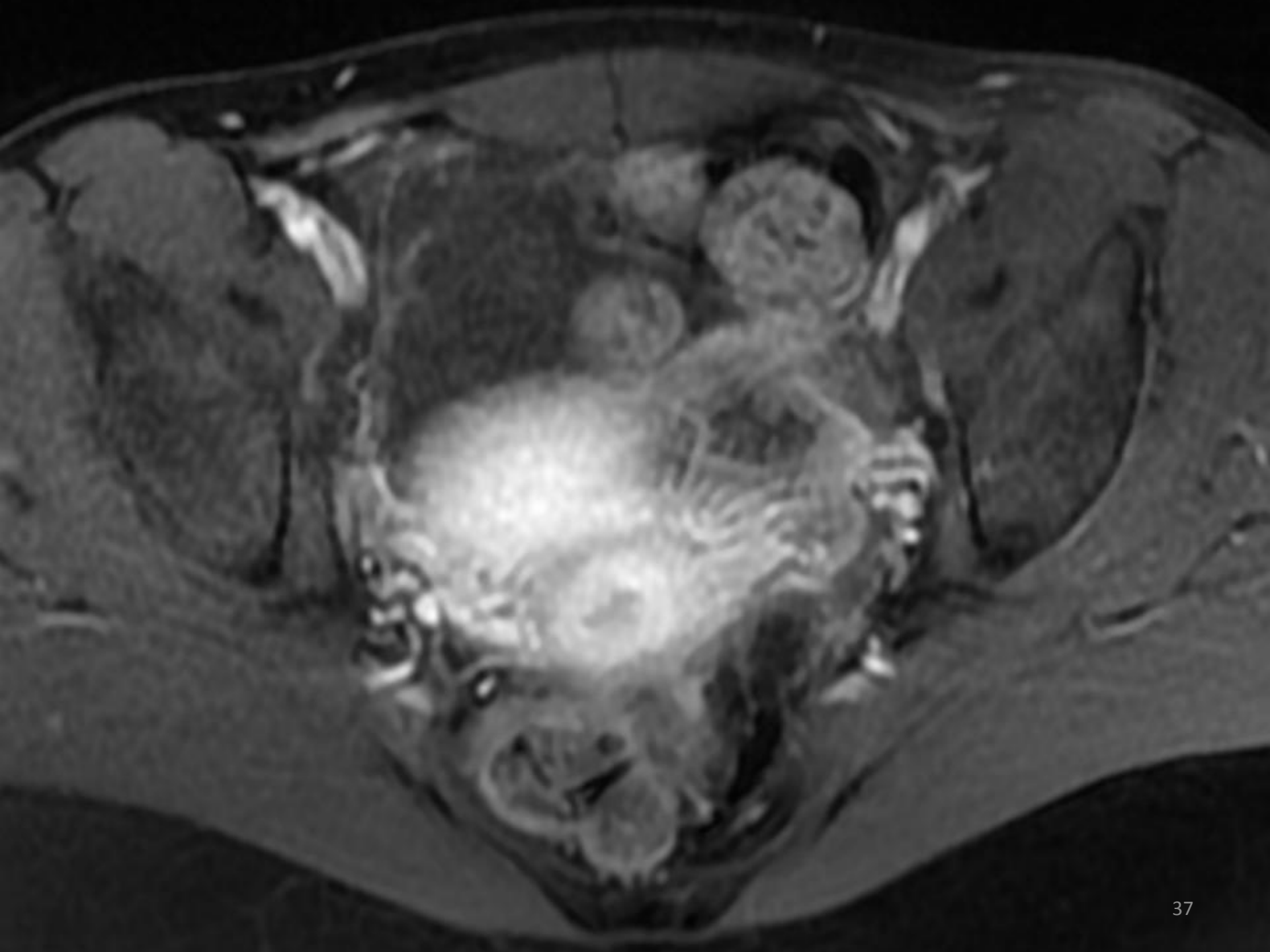


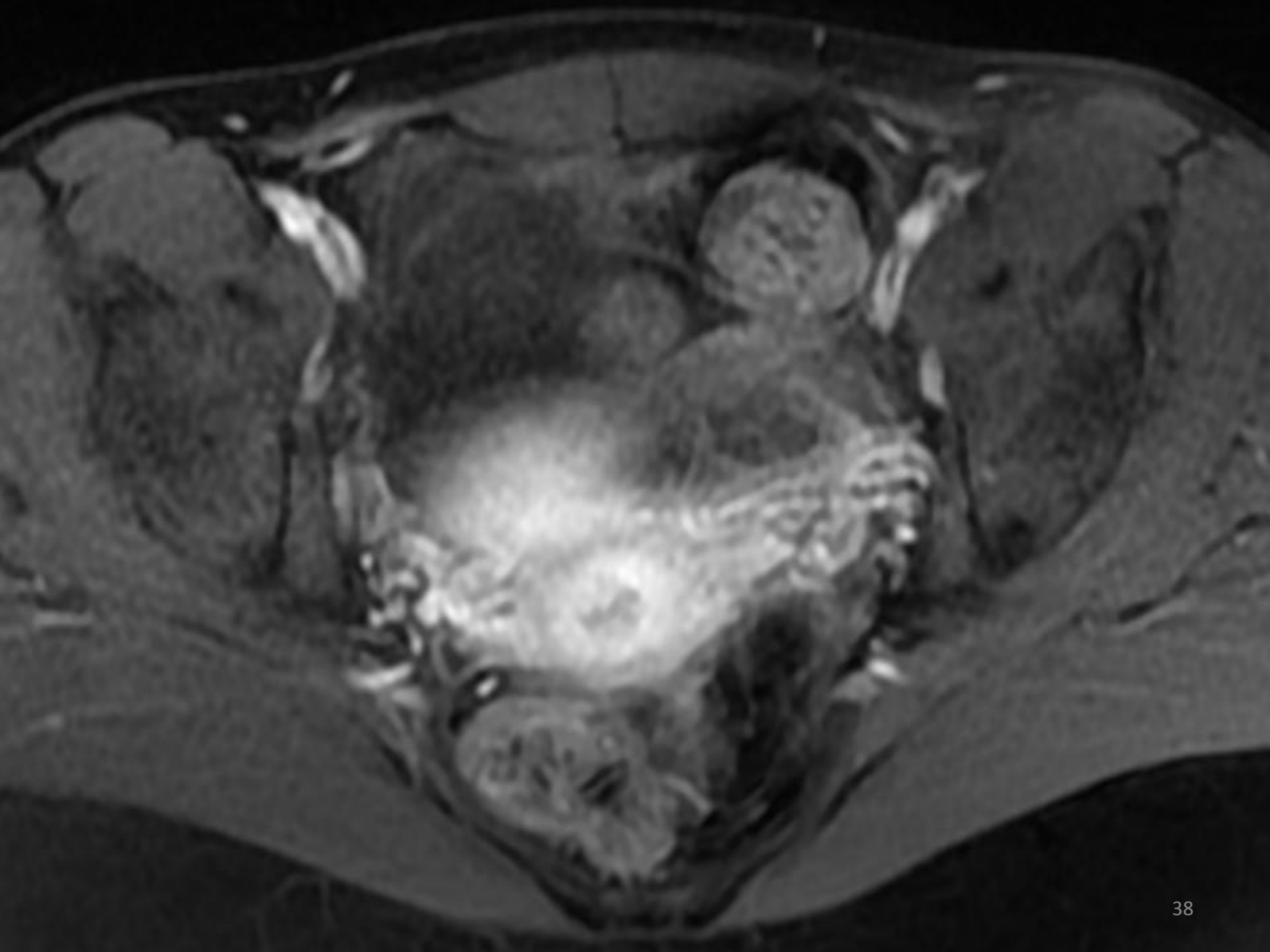


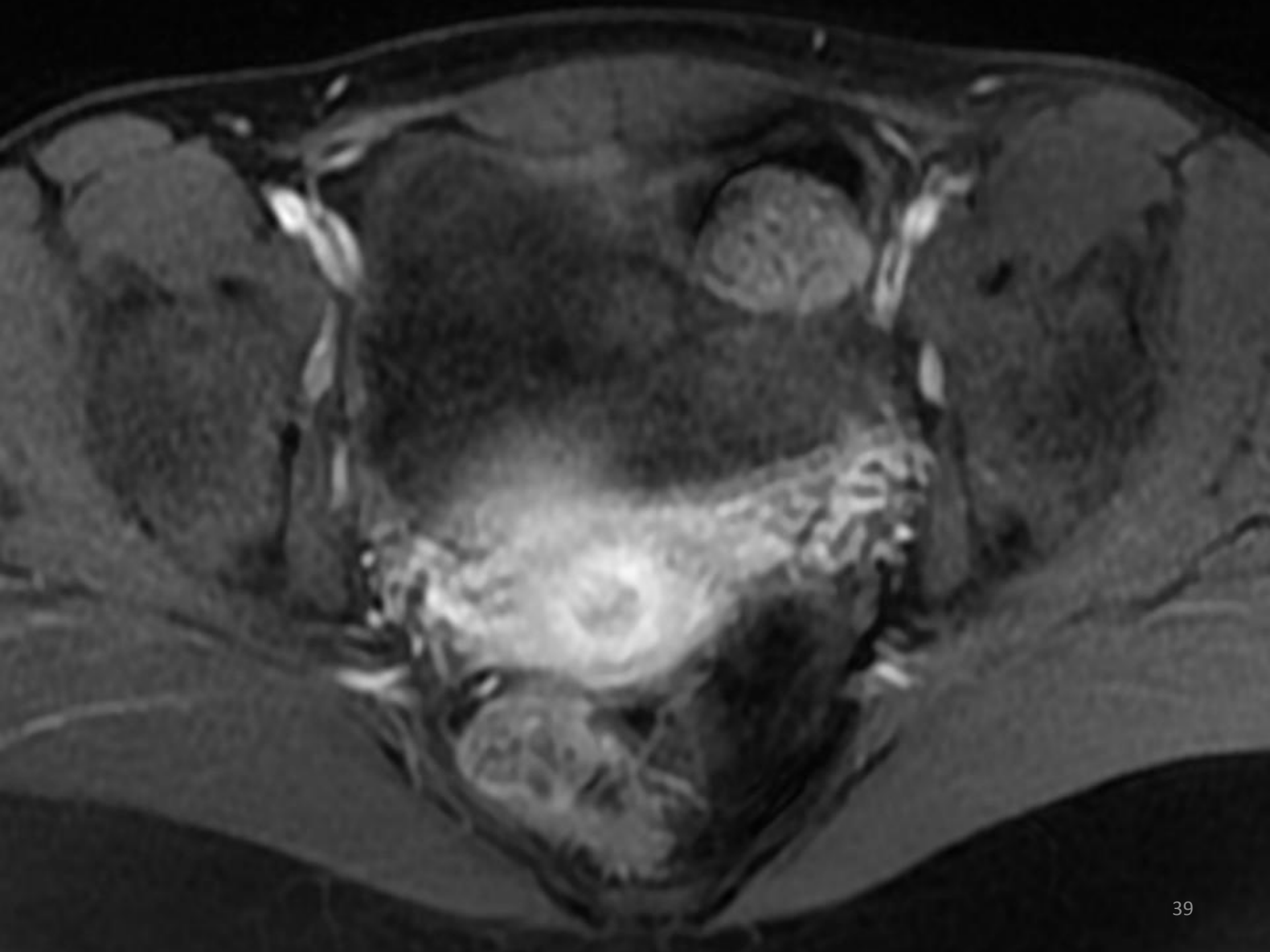








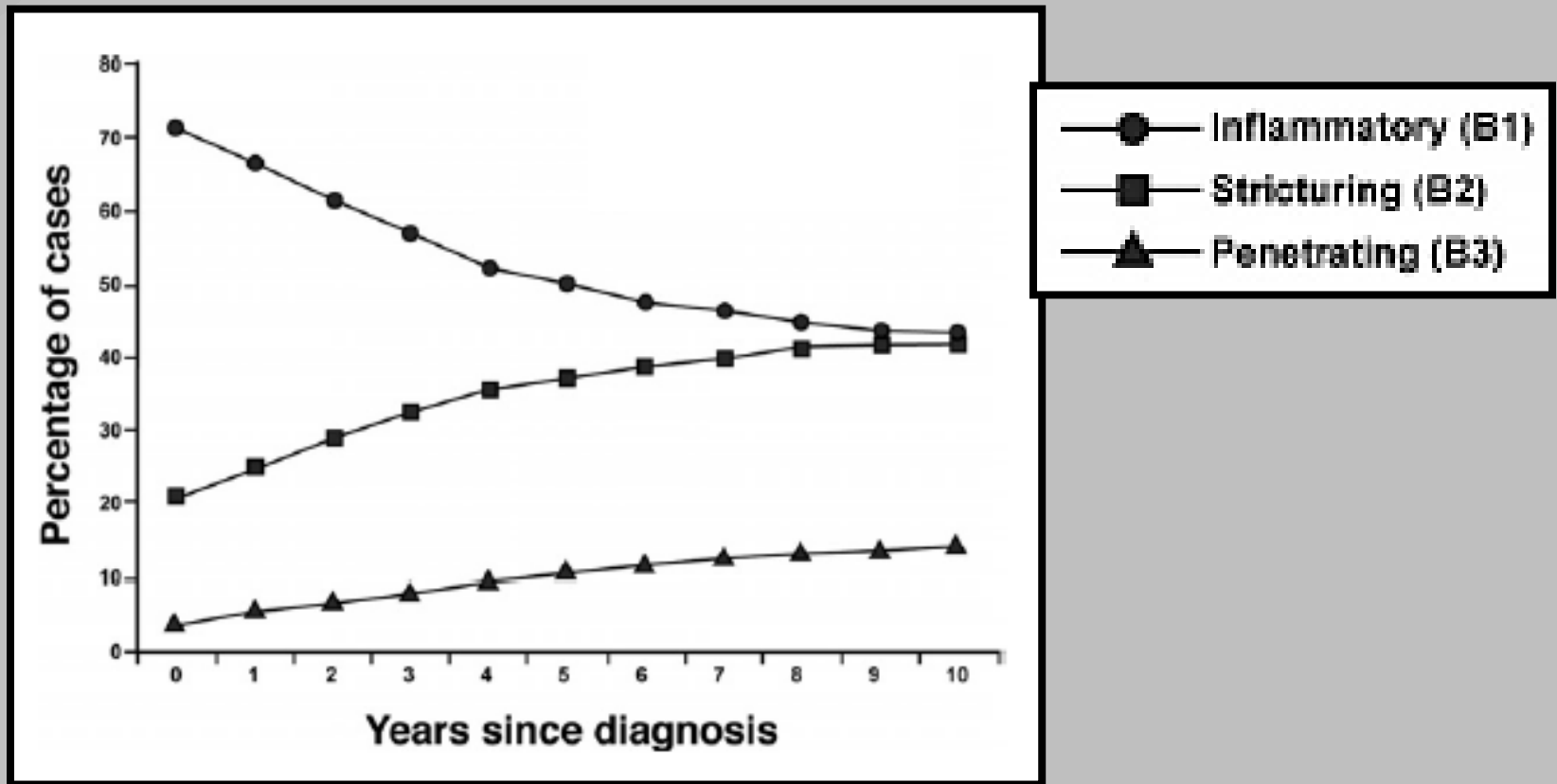




21y Old Female

- Although entered the study in clinical remission
- Mild abdominal pain
- Elevated CRP, Anemia
- MRE revealed extensive disease of the Terminal ileum: stenosis, sinus tract, abscess
- Treated with a course of prednisone

Crohn's Disease



1 = Natural History of Pediatric Crohn's Disease: A Population-Based Cohort Study; VERNIER-MASSOUILLE G. et al.; Gastroenterology 2008

Crohn's Disease

- Progressive and relapsing disease
- Patients are in risk to developing disease complications
- Better monitoring of Crohn's Disease (CD) patients will help us recognize patients in risk
- Targeted therapy

SHARE Study



- **Aim:** Developing an algorithm to predict relapse in Crohn's Disease (CD) patients
- **Methods:**
 - **MR Enterography (MRE)** - yearly
 - **Capsule endoscopy** (PillCam SB3 or PillCam C2) - every 6M
 - **Extensive Laboratory** - Every 3M

MR Enterography

- One of the main tools in diagnosing, staging and monitoring of CD patients
- Non ionizing radiation
- High contrast resolution
- Lower incidence of adverse events related to IV contrast employed
- Compared to CTE

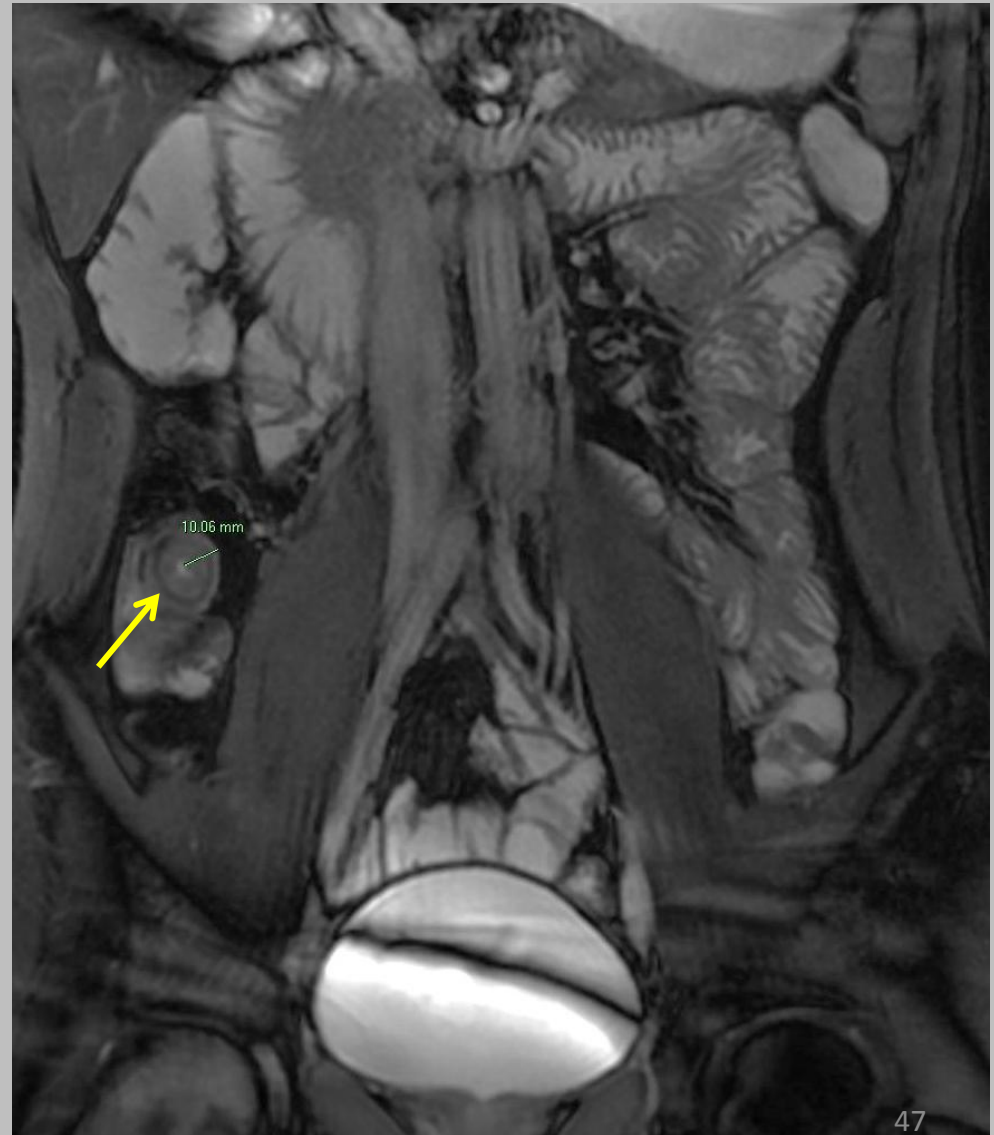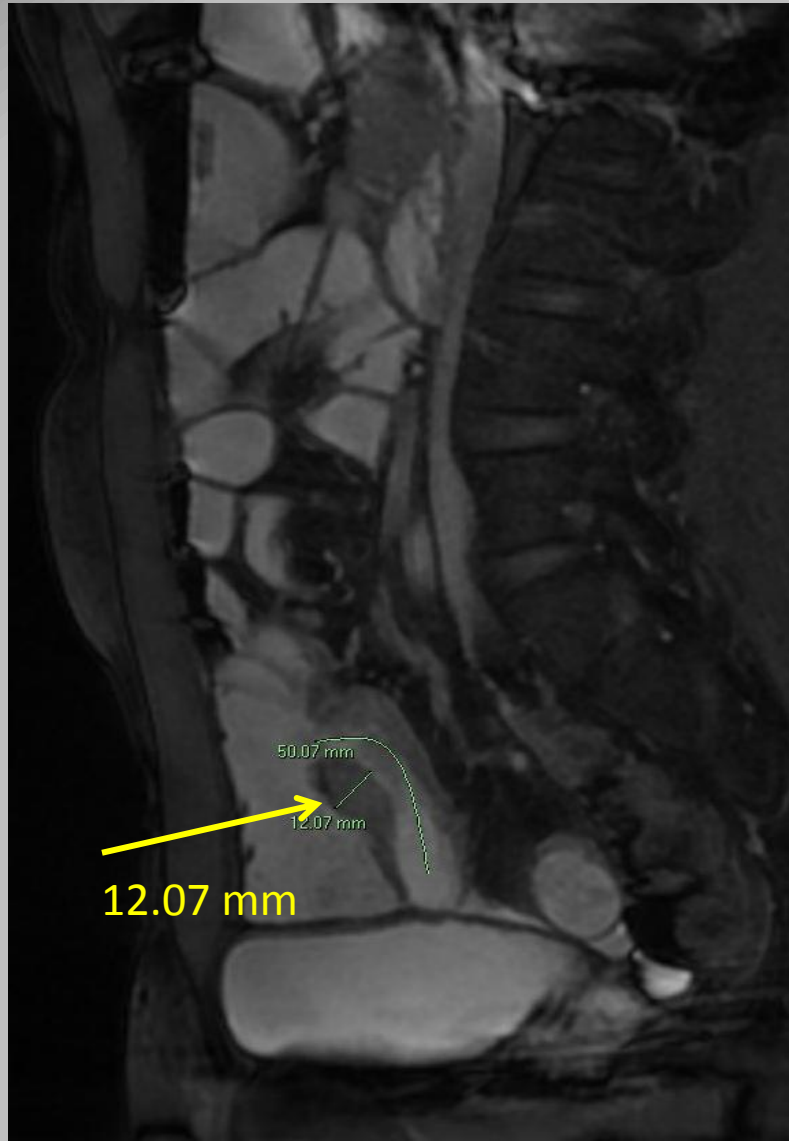
What are we looking for?

- Mural thickening
- Luminal narrowing (stenosis)
- Pre stenotic dilatation
- Post gadolinium enhancement
- Extra mural disease
 - Fistula, Abscess
 - Mesenteric congestion-“comb sign”
 - Lymphadenopathy
- Diffused Weighted Imaging (DWI)

What are we looking for?

- Mural thickening
- Luminal narrowing (stenosis)
- Pre stenotic dilatation
- Post gadolinium enhancement
- Extra mural disease
 - Fistula, Abscess
 - Mesenteric congestion-“comb sign”
 - Lymphadenopathy
- Diffused Weighted Imaging (DWI)

T2 with fat suppression

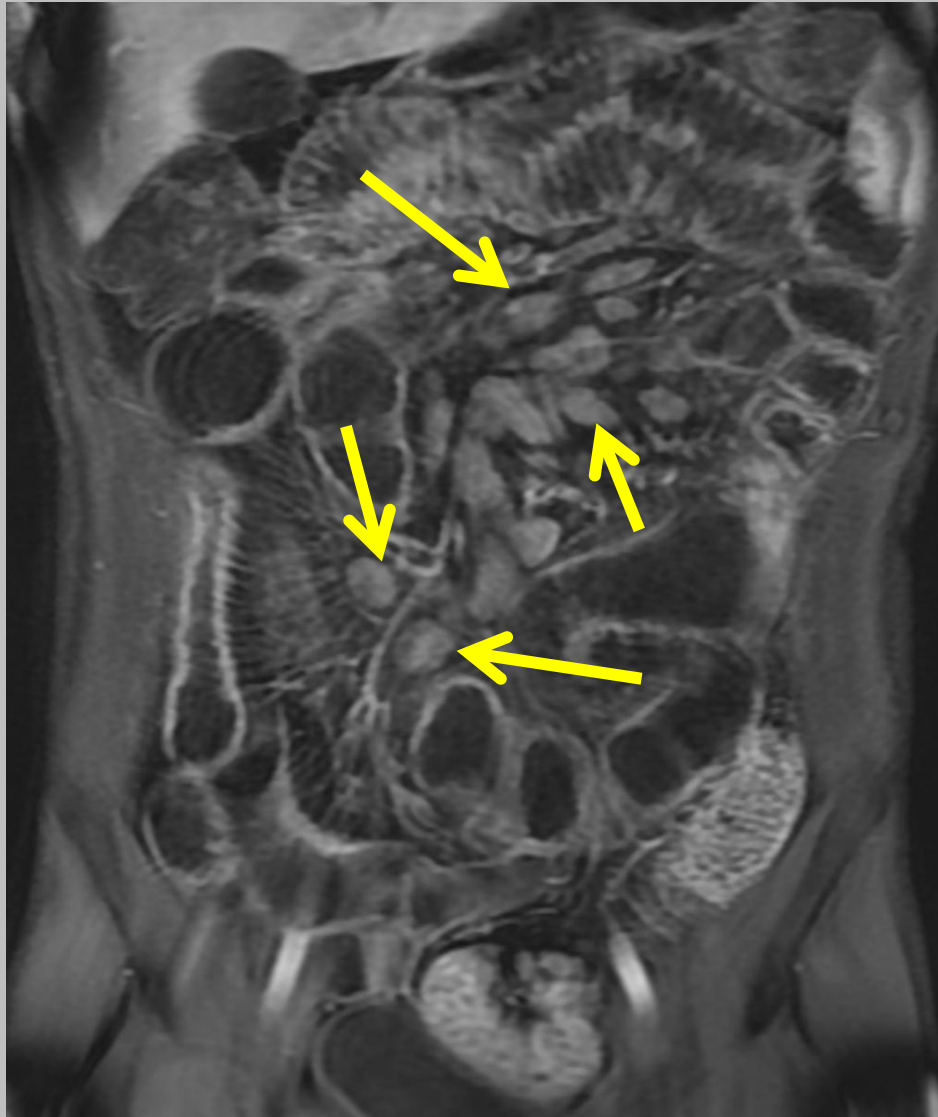


What are we looking for?

- Mural thickening
- Luminal narrowing (stenosis)
- Pre stenotic dilatation
- Post gadolinium enhancement
- Extra mural disease
 - Fistula, Abscess
 - Mesenteric congestion-“comb sign”
 - Lymphadenopathy
- Diffused Weighted Imaging (DWI)

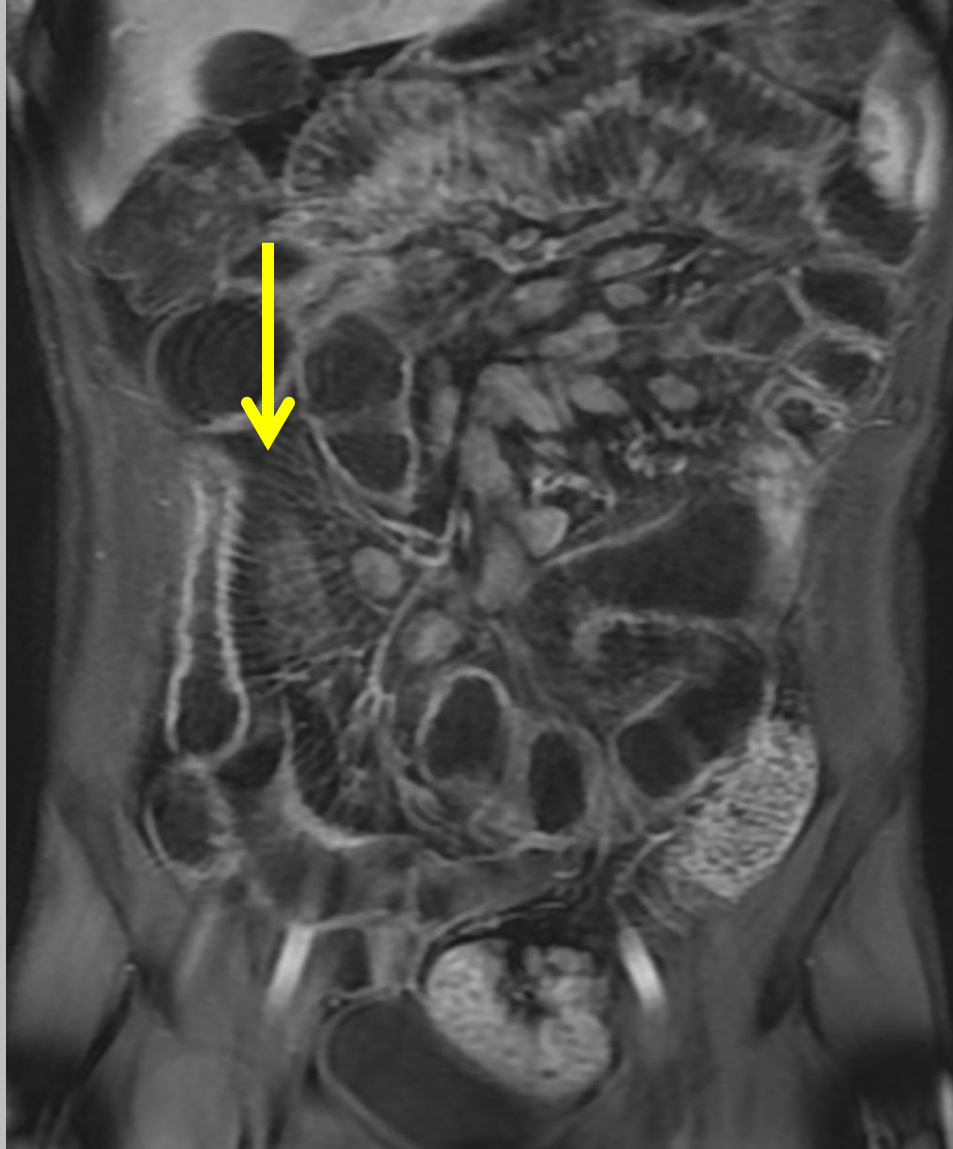Lymphadenopathy

T1 post gadolinium



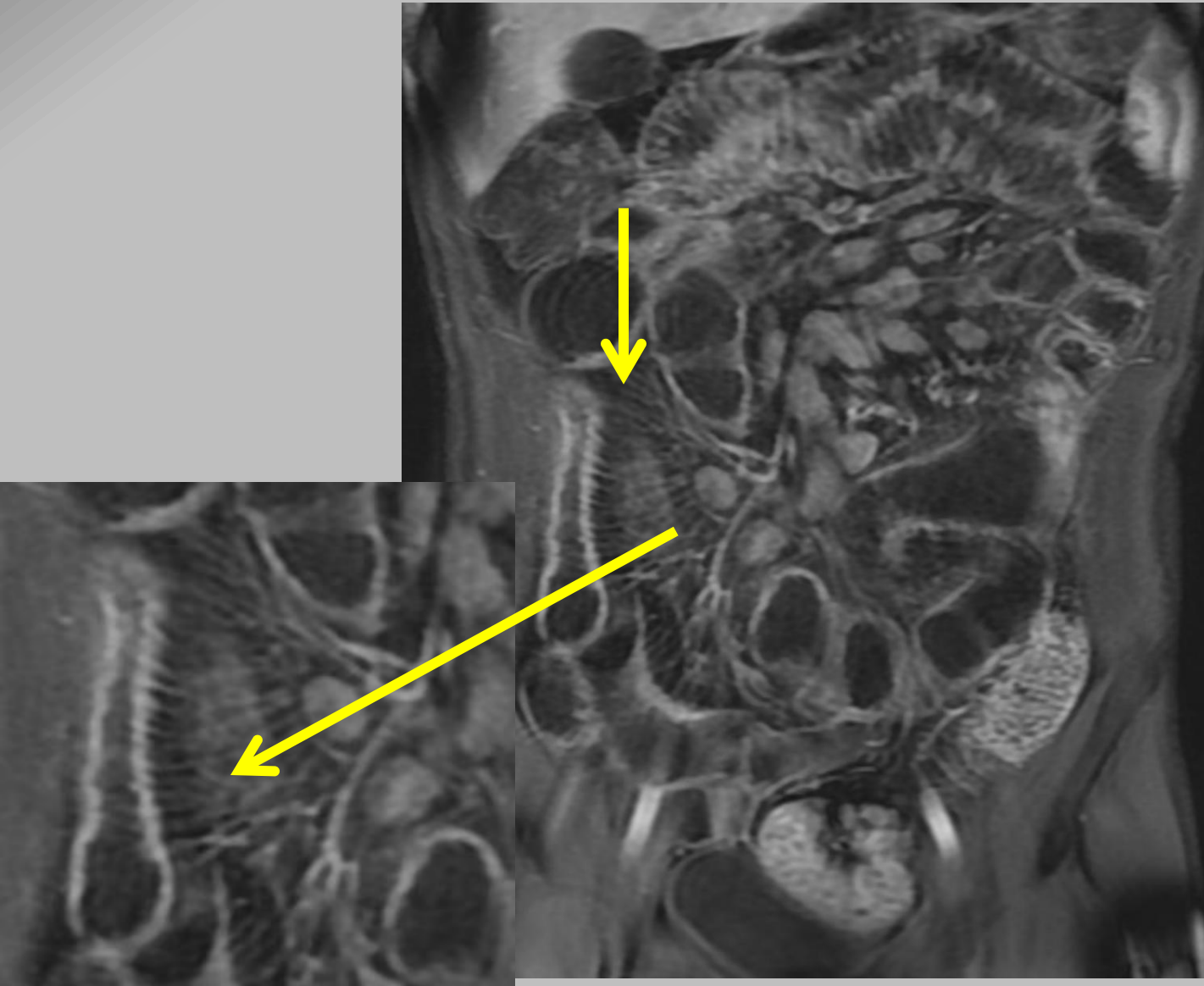
Comb sign

T1 post gadolinium



Comb sign

T1 post gadolinium



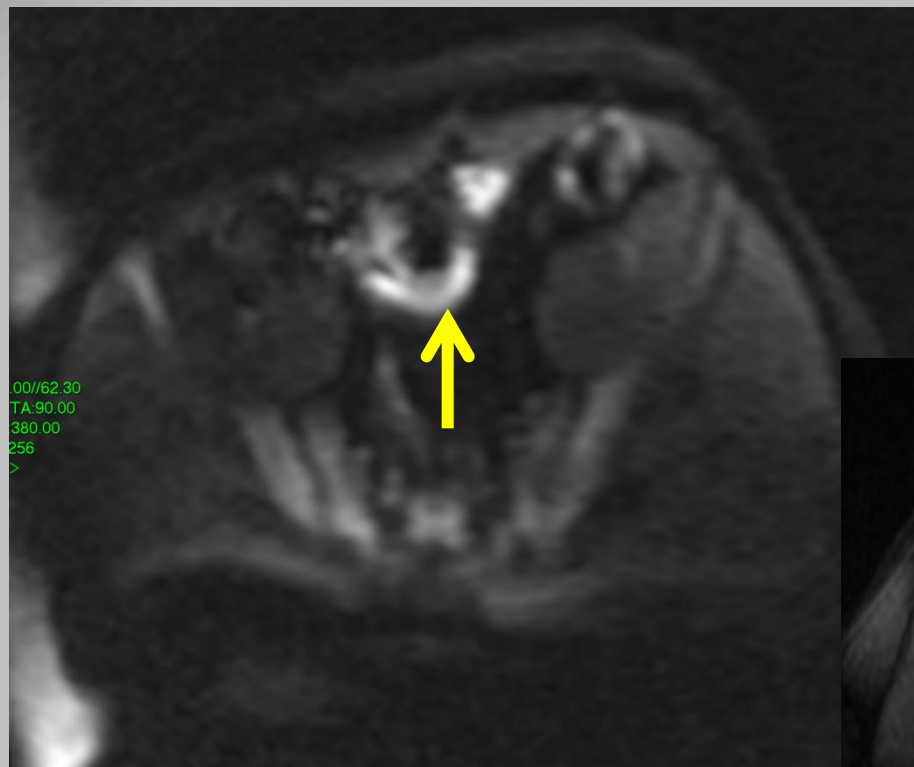
What are we looking for?

- Mural thickening
- Luminal narrowing (stenosis)
- Pre stenotic dilatation
- Post gadolinium enhancement
- Extra mural disease
 - Fistula, Abscess
 - Mesenteric congestion-“comb sign”
 - Lymphadenopathy
- Diffused Weighted Imaging (DWI)

DWI

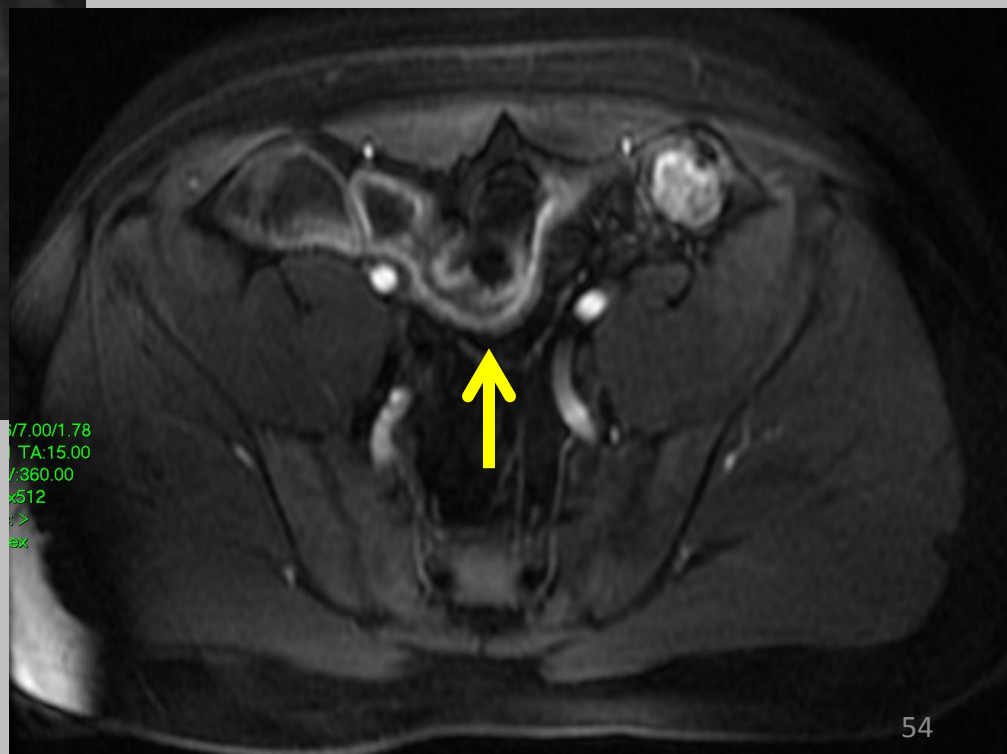
- MRI sequence
- Based on random water movement
- Contrast resolution - difference in the motion of water molecules between tissues

27y Old Male



DWI

T1 + C

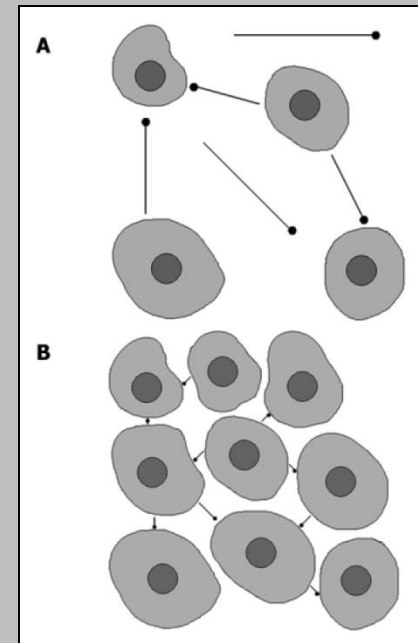


DWI

- Detect **restricted diffusion** of water

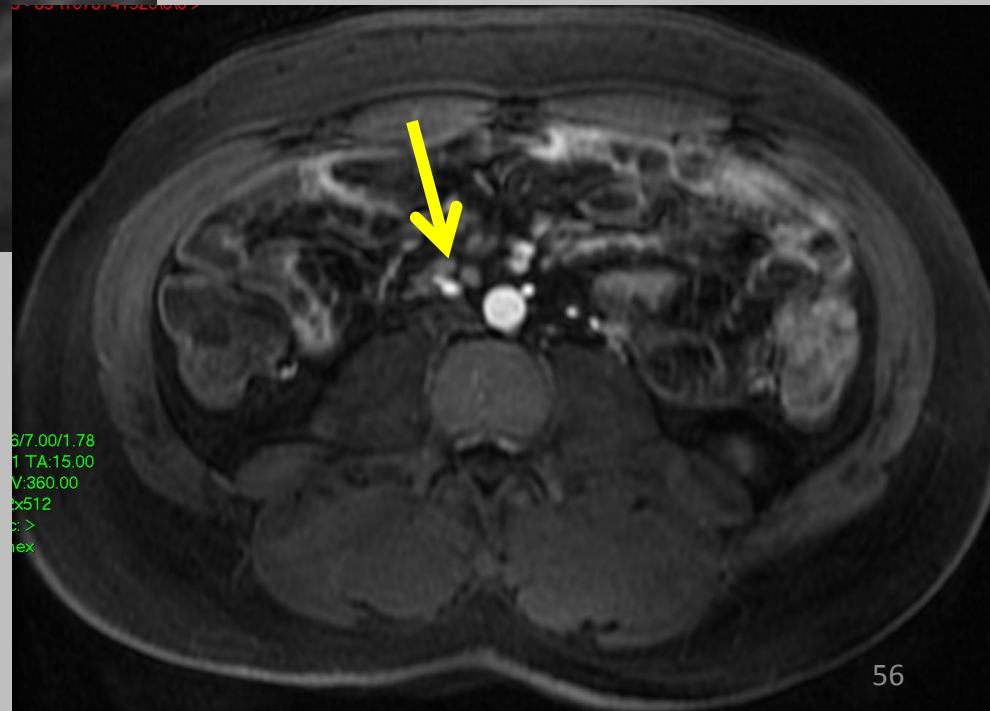
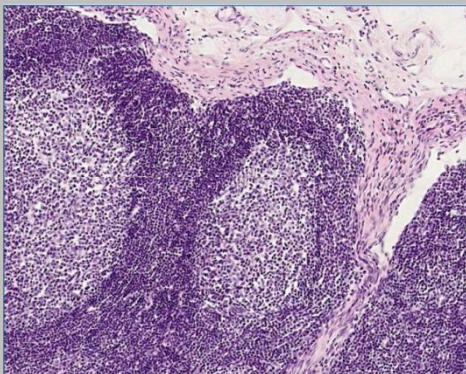
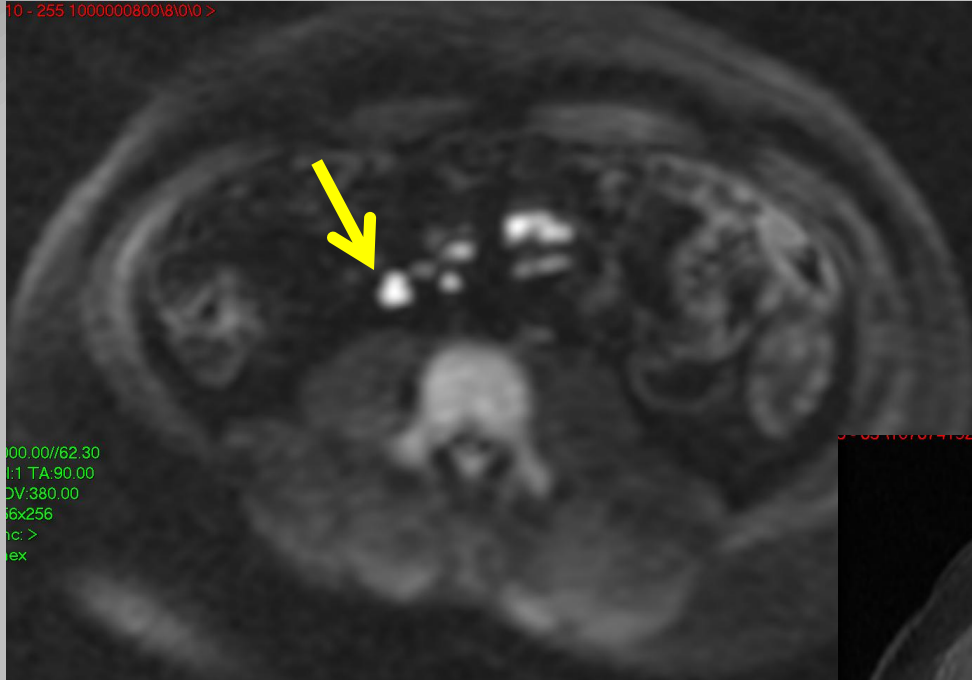
Unrestricted

Restricted



- DWI is under broad research for possible implications in IBD imaging

27y Old Male




SHARE Study



- **Aim:** Developing an algorithm to predict relapse in Crohn's Disease (CD) patients
- **Methods:**
 - **MR Enterography (MRE)** - yearly
 - **Capsule endoscopy** (PillCam SB3 or PillCam C2) - every 6M
 - **Extensive Laboratory** - Every 3M

Capsule endoscopy



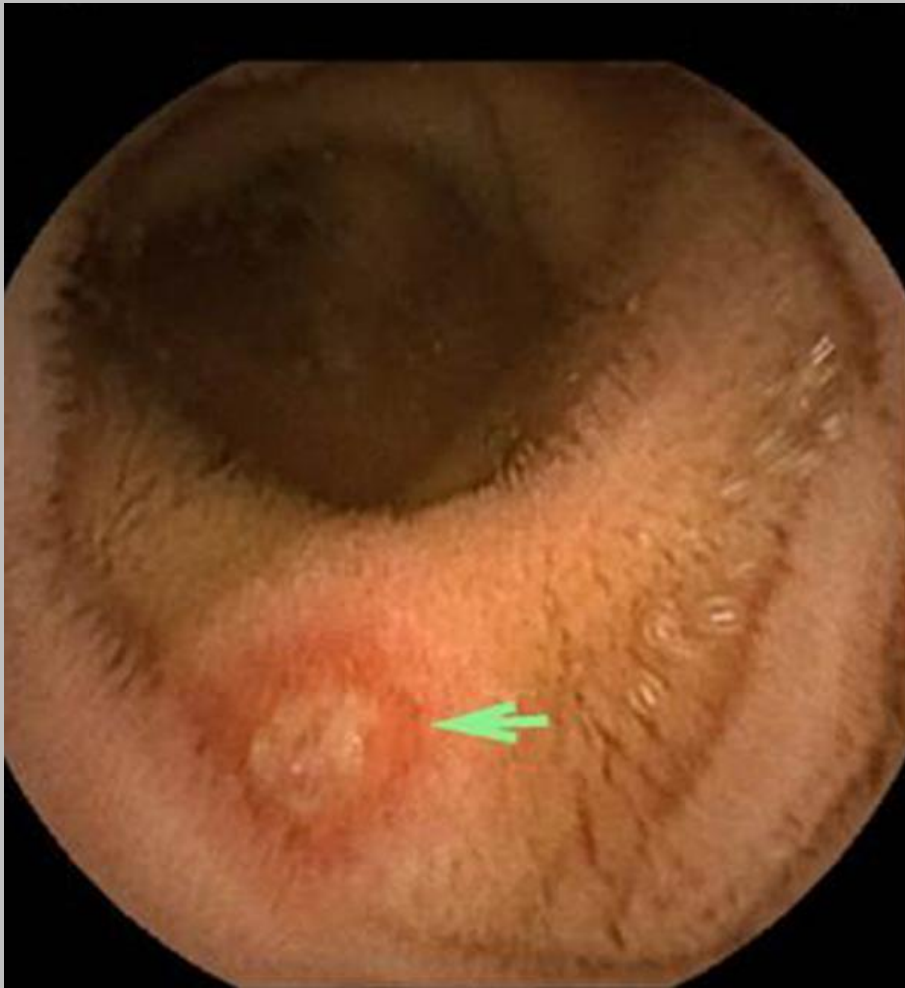
- Capsule endoscopy – in clinical use from 2001
- Non invasive, user friendly, painless technique
- Enabling visualization of the entire small bowel mucosa



* Courtesy of Prof. Rami Elyakim

Capsule endoscopy

Aphthae



Cobblestone



Methods

B	C	D	E	F	G	O	P	Q	R	S	T	U	V
I.D	Sex	Age	Ileocectomy	Date of first exam	UDT	SB 1	Leagnth of segment	Pre-stenotic dilatation	Stenosis	Fistula	Abscess	Mural thickening	Mural enhancemnt
66502170	M	29	hinal ileum - 10	17.10.2013	Duodenum	DI	7 cm	0	0	0	0	0	1
49818156	M	31		4.8.2013	0	DI	4 cm	1	1	0	0	1 - 9 mm	1
26492694	F	27		19.11.2013	0	0							
22060735	M	47		24.11.2013	0	NTI	2 cm	0	1	0	0	1 - 6.21 mm	1
37310901	M	34		15.12.2013	0	0							
200834422	F	24		22.12.2013	0	0							
22362412	F	45		1.12.2013	0	0							
300559572	F	27		1.12.2013	0	0							
33872912	M	36		8.12.2013	0	TI	3 cm	1	1	0	0	1 - 10 mm	1
33815815	M	38		8.12.2013	0	TI	3 cm	1	1	0	0	1 - 10 mm	1
300228215	F	31		1.12.2013	0	0							
33365415	F	42		1.12.2013	0	0							

Y	AI	AS	BC	BK	BS	CA	CI	CQ	CY	DG	DH	DI	DJ	DK	DL	DM	DN	DO
SB 2	SB3	SB4	Cecum	AC	TC	DC	SC	Rectum	Anus	נתונים נוספים	Ileocecal valve involvement	Ascitis	Mesenteric hypertrophy	phoadenop	Comb sign	Capsule blocking	Extraenteric findings	Perianal disease
0	0	0	0	0	0	0	0	0	0		0	0	0	0	0	Y	0	0
TI	PI	0	0	0	0	0	0	0	0		1	1	1	0	1	Y	0	0
0	0	0	0	0	0	0	0	0	0		0	0	1	0	0	N	0	0
DI	0	0	0	0	1	0	0	0	0		1	0	1	0	0	N	0	0
0	0	0	0	0	0	0	0	0	0		0	0	0	0	0	N	0	0
0	0	0	0	0	0	0	0	0	0		0	0	0	0	0	N	0	0
0	0	0	0	0	0	0	0	0	0		0	0	0	0	0	N	0	0
0	0	0	0	0	0	0	0	0	0		1	0	1	0	1	Y	0	0
DI	DI	0	0	0	0	0	0	0	0		1	1	1	1	1	Y	0	0
PI	DJ	0	0	0	0	0	0	0	0		0	1	1	1	1	Y	0	0
PJ	0	0	0	0	0	0	0	0	0		1	0	1	1	1	Y	0	0
DI	DI	0	0	0	0	0	0	0	0		1	0	1	0	0	N	0	0
0	0	0	0	0	0	0	0	0	0		1	0	1	1	1	Y	0	0
0	0	0	0	0	0	0	0	0	0		1	0	1	1	1	Y	0	0
DI	DI	0	0	0	0	0	0	0	0		1	0	1	0	0	N	0	0
DI	DI	0	0	0	0	0	0	0	0		1	0	1	0	0	N	0	0
DI	DI	0	0	0	0	0	0	0	0		1	0	1	0	0	N	0	0
DI	DI	0	0	0	0	0	0	0	0		1	0	1	0	0	N	0	0

**Radiology research project
from the data collected in the
SHARE study**

```
graph TD; A[Radiology research project from the data collected in the SHARE study] --> B[MRE prediction of patency capsule retention]; A --> C[Diffusion in Upper Gastrointestinal tract]; A --> D[Correlation between MRE and capsule endoscopy]; A --> E[Validation of Lemann score];
```

MRE prediction of patency
capsule retention

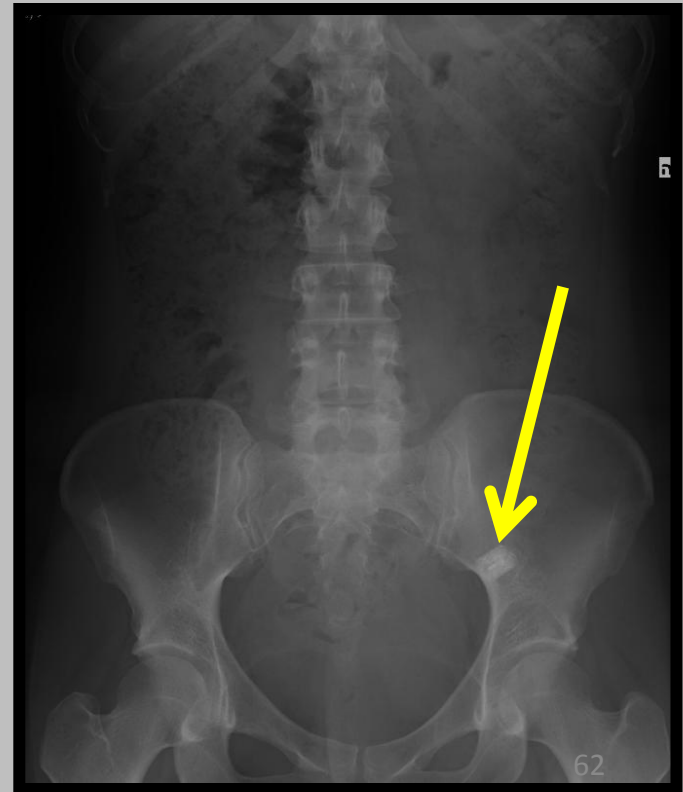
Diffusion in Upper
Gastrointestinal tract

Correlation between MRE and
capsule endoscopy

Validation of Lemann
score

MRE prediction of “patency capsule” retention

- **Main complication:** Capsule retention leading to iatrogenic surgery
- Rate of retention: up to 13%



MRE prediction of “patency capsule” retention

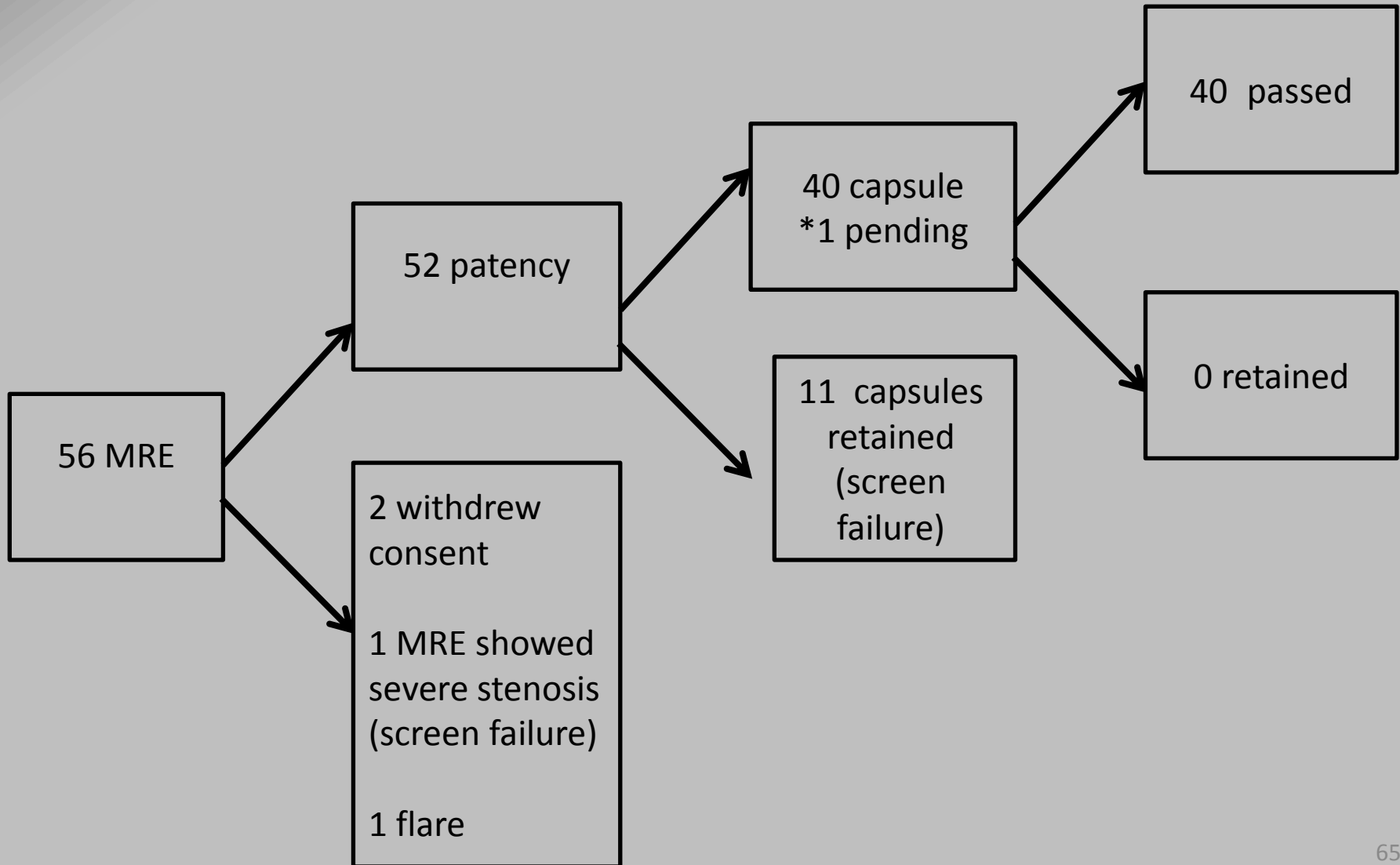
- Patency capsule
- Self dissolving – after 30h
- Screen patients for patency of gastrointestinal tract



MRE prediction of patency capsule retention

- Aim: To evaluate the ability of MRE to predict retention of “patency capsule”

Preliminary results (9 month)



Preliminary results (9 month)

	MRE	Patency results
Patency will not retain	29	41
Patency will retain	23	11

- All patients with retained patency were predicted by MRE

Validating Capsule passage

- Sensitivity of the MRE to predict retention - 100% (11/11)
- The specificity of the MRE to predict patency – 70% (29/41)
- PPV – 47% (11/23)
- NPV – 100% (29/29)

Validating Capsule passage

Next step: Is there any quantitative correlation between

- number of segments involved
- length of segments
- wall thickness

and retention

**Radiology research project
from the data collected in the
SHARE study**

```
graph TD; A[Radiology research project from the data collected in the SHARE study] --> B[MRE prediction of patency capsule retention]; A --> C[Diffusion in Upper Gastrointestinal tract]; A --> D[Correlation between MRE parameters and capsule endoscopy]; A --> E[Validation of Leman score];
```

MRE prediction of patency
capsule retention

Diffusion in Upper
Gastrointestinal tract

Correlation between MRE
parameters and capsule
endoscopy

Validation of Leman score

Thank you for listening...

And for all the students...

Have a Great Summer !!

